



# **CARE BEYOND CURE**


Dr. Ashish Abraham Thankachan  
Managing Director  
Madhipura Christian Hospital





# DISCLOSURE

No relevant financial relationships with ineligible companies to disclose.



## **Learning Objectives**

---

To understand the concept of Comprehensive Patient Care.

---

To comprehend the importance of patient safety in Patient Care.

---

To practice the model of Care Beyond Cure



Prem Jyoti Community Hospital

Madhipura Christian Hospital  
मधेपुरा क्रिश्चियन अस्पताल

Number of Beds : 30  
Target Population : Malto Tribe  
Primary/ Secondary care  
Nearest Referral centre : 70 KM

Number of Beds : 100  
Target Population : Musahar  
Secondary-Higher  
Secondary/Tertiary care  
Nearest Referral centre : 200 KM

Tale of Two Hospitals


# Present Challenges

- Primitive Living
- Accessibility – Hilly terrain
- Health not a priority
- Traditional Tribal alternatives
- Poor and the Marginalized
- Caste Burden
- Gender Preference
- Local Quacks



RURAL  
HEALTHCARE

URBAN  
HEALTHCARE





# RISE OF MEDICAL MISSION

R – RELEVANCE

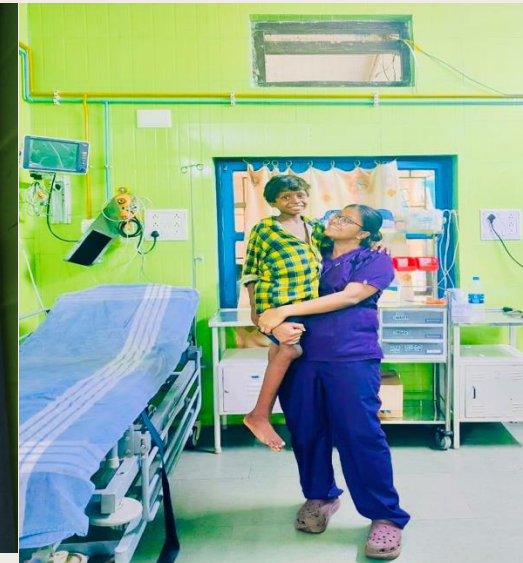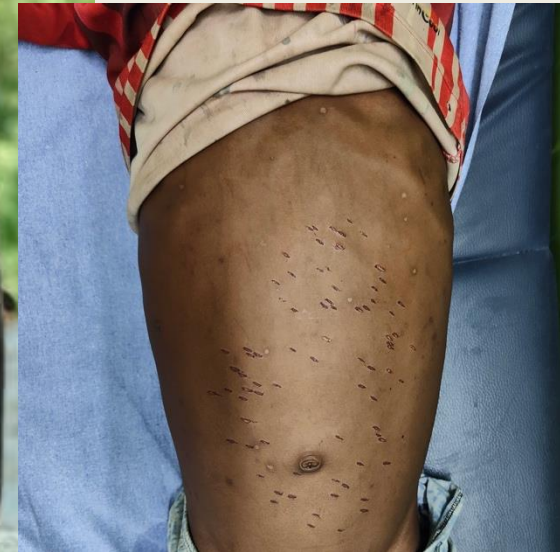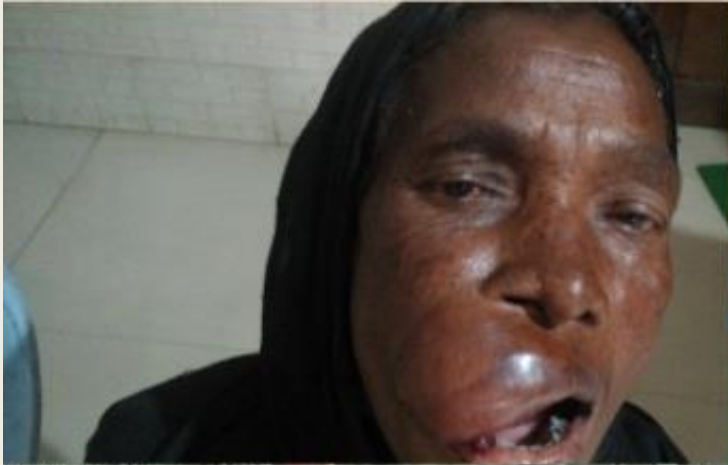I – INTEGRITY

S – SELFLESSNESS

E – EXCELLENCE

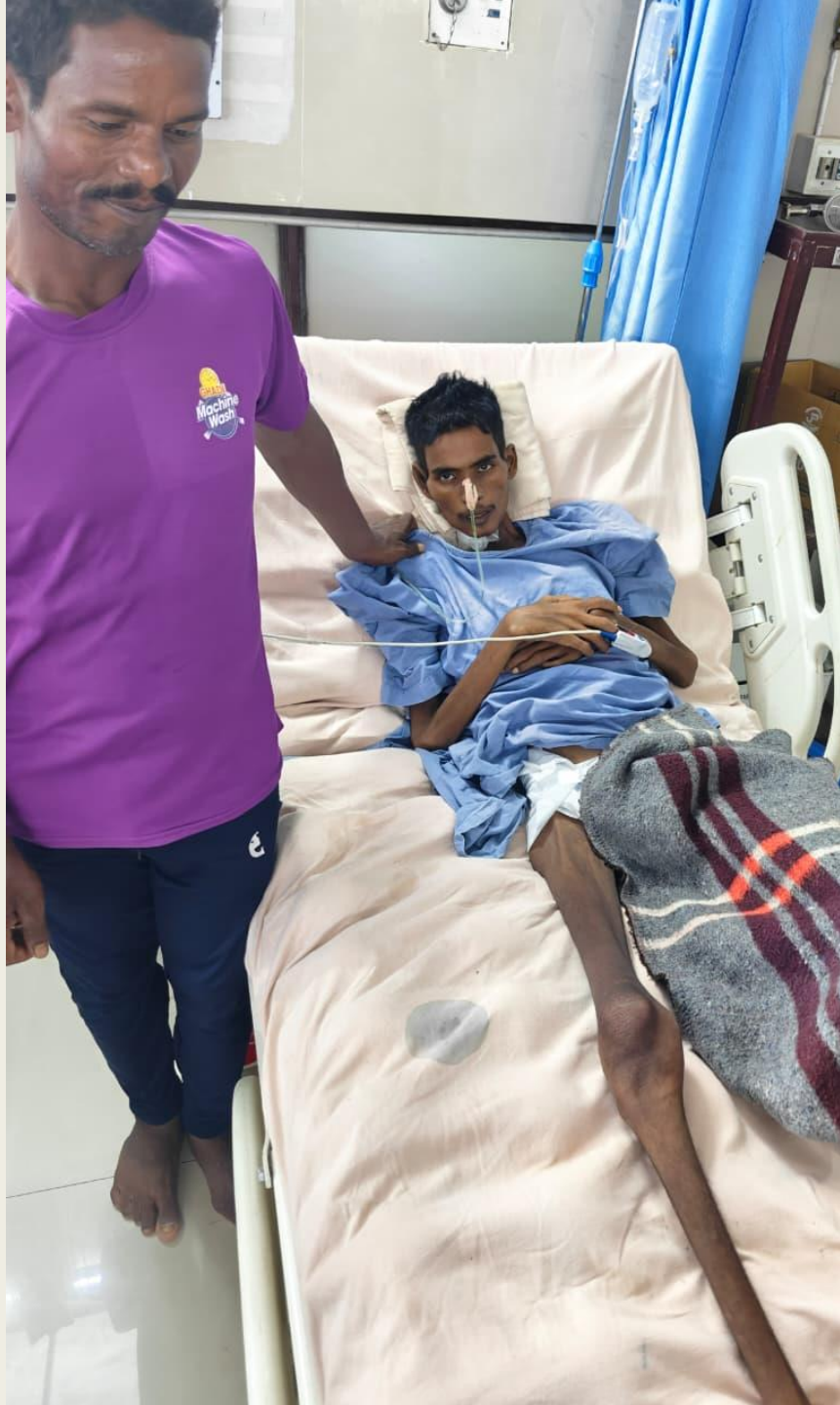

# COMPREHENSIVE PATIENT CARE



Holistic Treatment

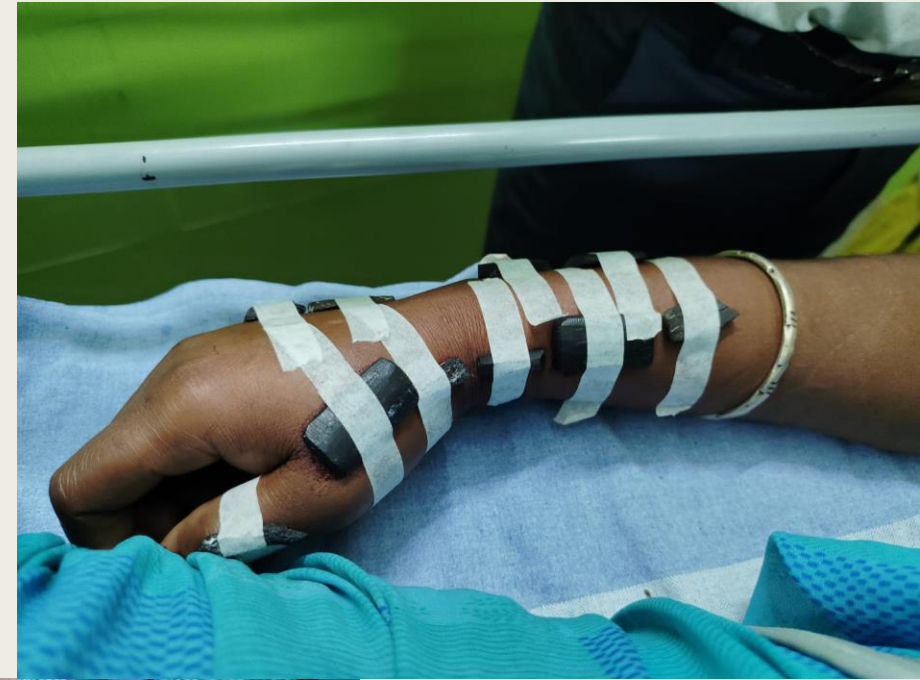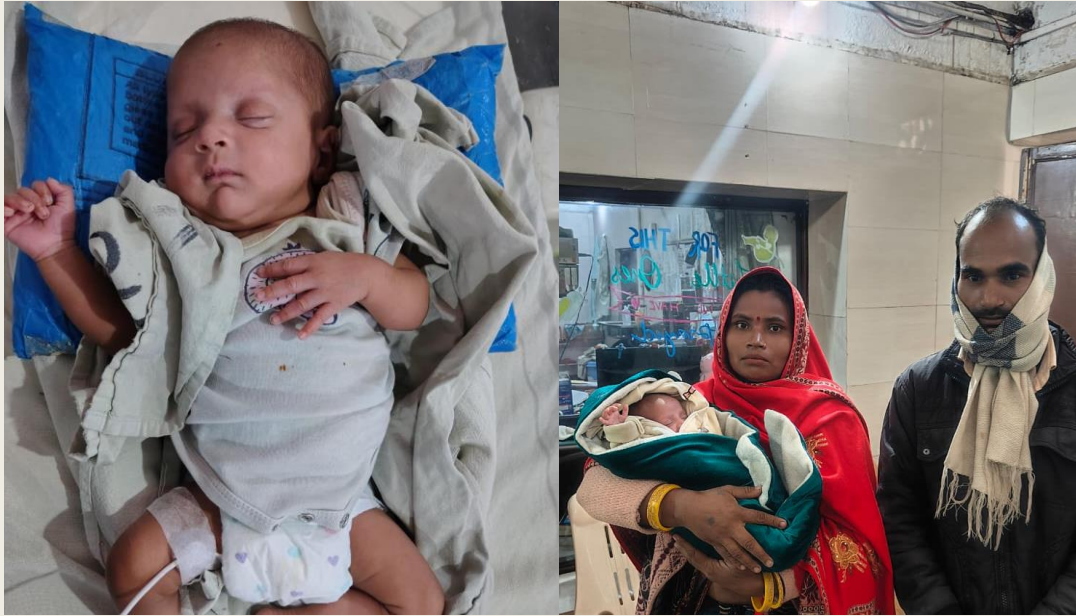Patient First Approach



# No Turning Away

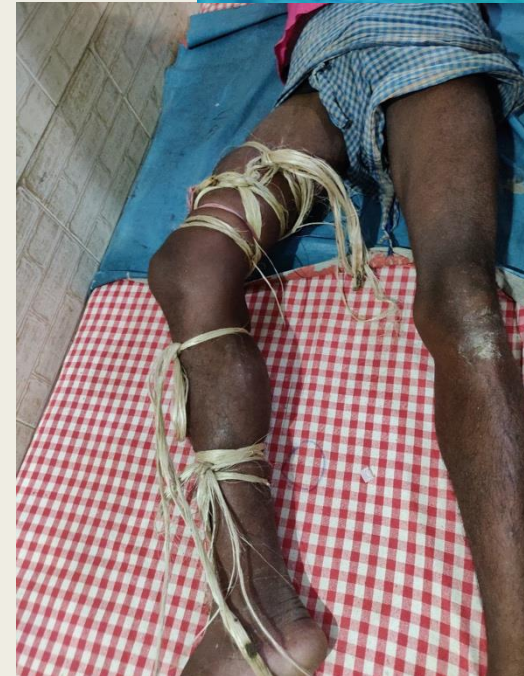- Who is the Last resort ?
- No Referrals





## Equitable in Quality and Safety

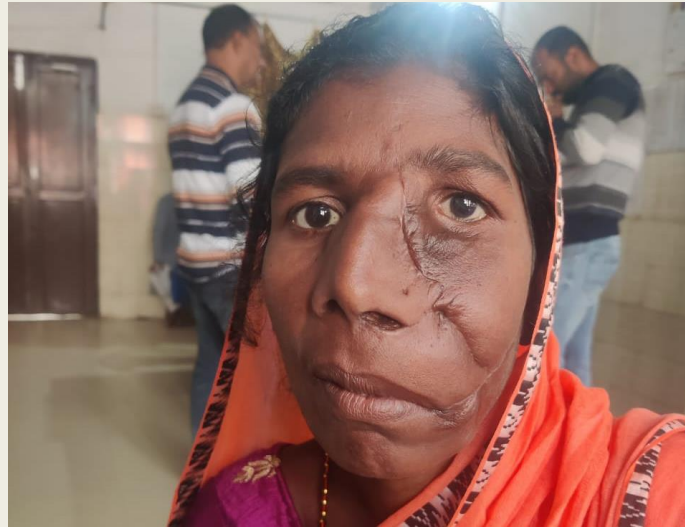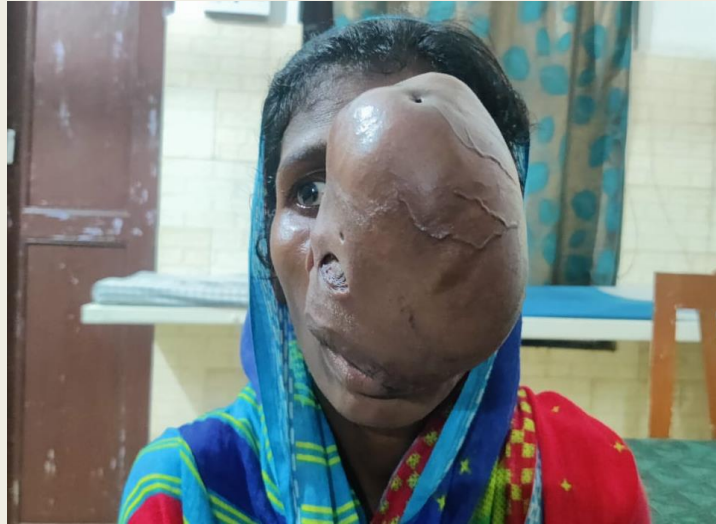- Protocol based treatment
- Tele-Consultation with experts
- Generalist over Specialist



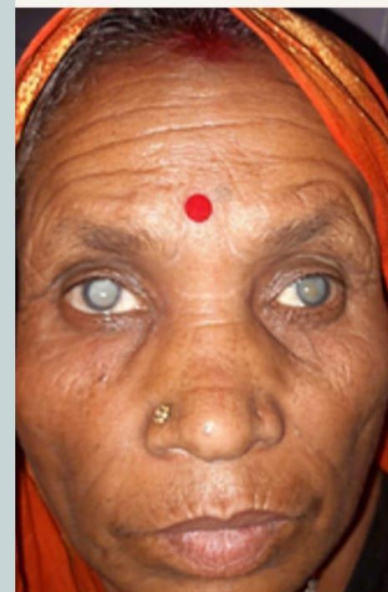# Respectful Maternal Care



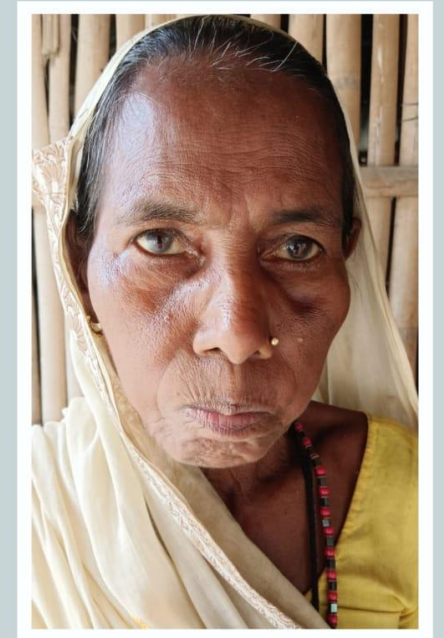
# Healing at the Camps



- Services not available at the hospital are provided through regular medical camps.
- Visiting specialists provide expert care rarely accessible to the marginalized



BEFORE



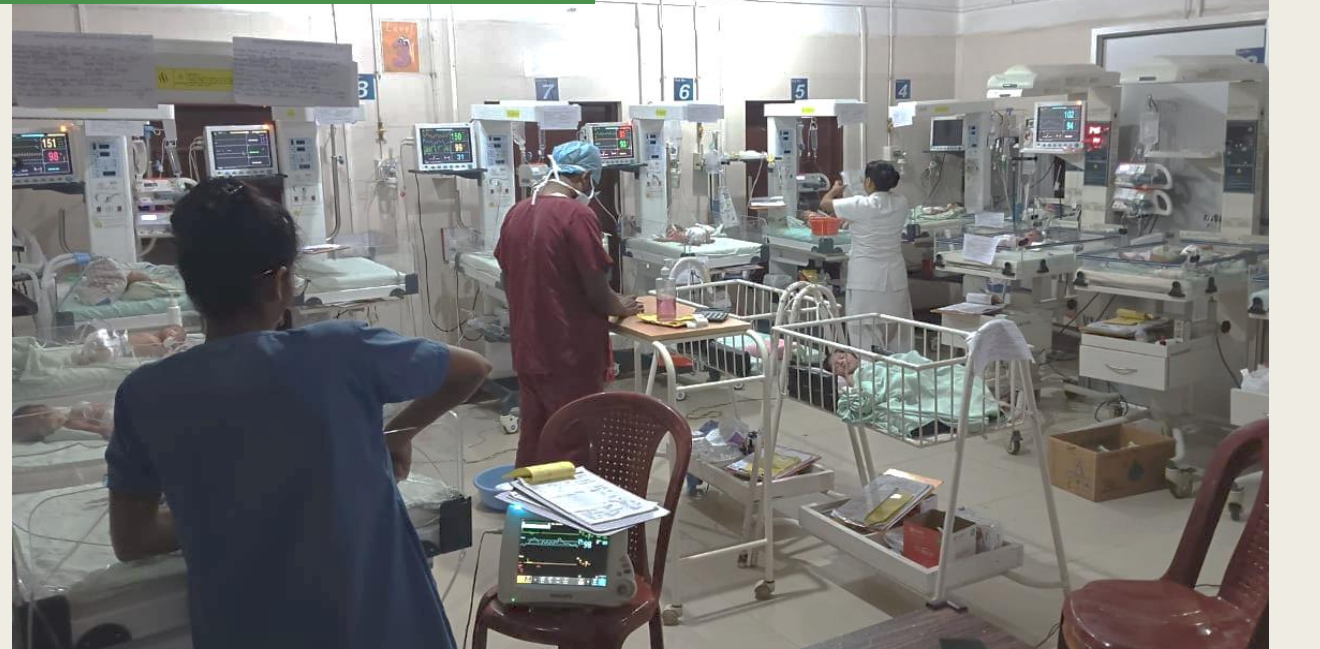AFTER

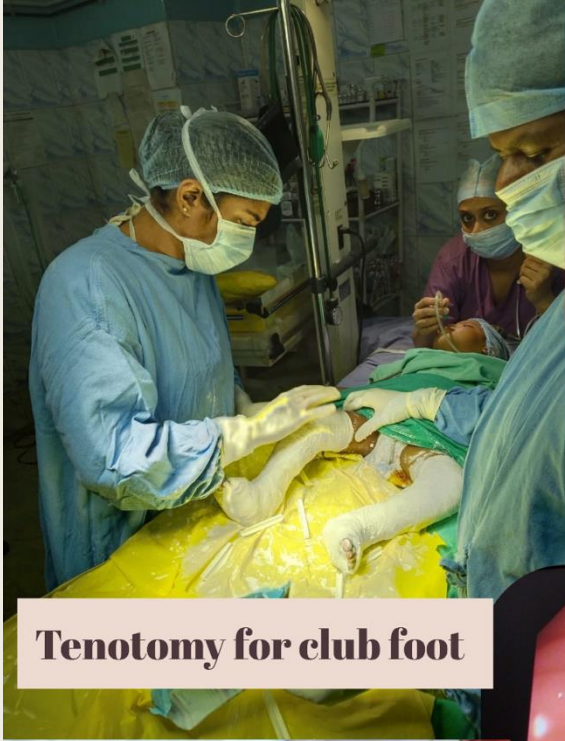

KREIDER  
OT COMPLEX

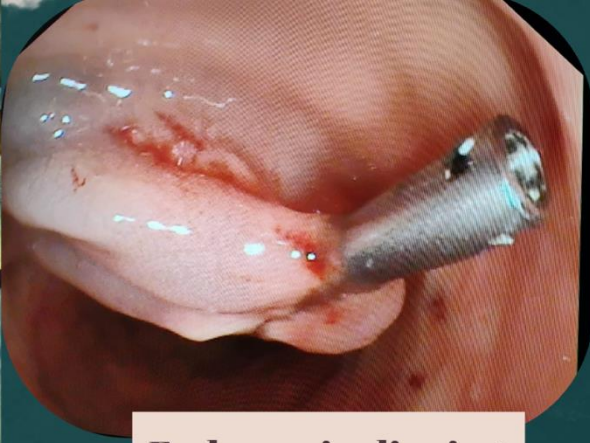LOWELL MANN  
INTENSIVE CARE UNIT

# Secondary Vs Tertiary Care





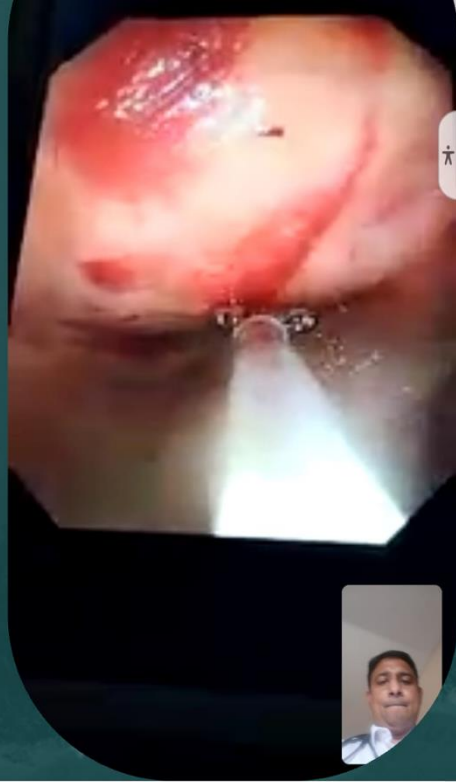
**Tenotomy for club foot**



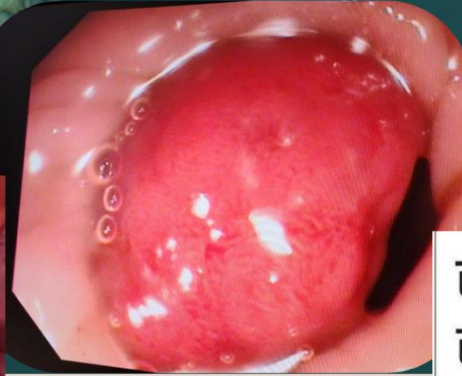
**Endoscopic clipping of bleeders**



**Community Dental Services**

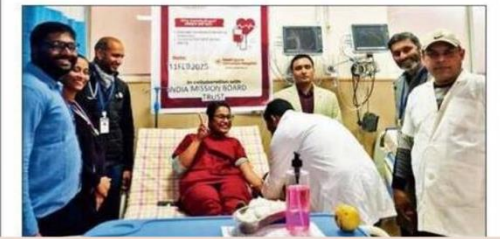

**Chemo administered**



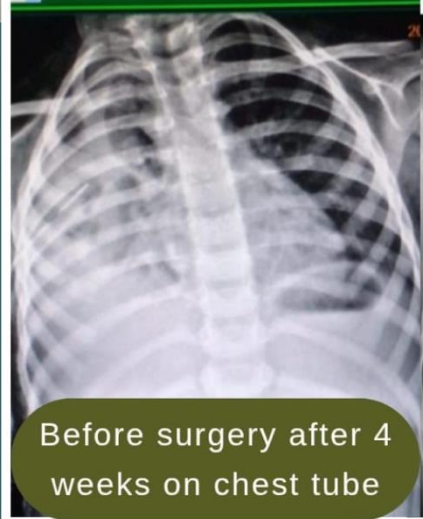**Colonoscopic snaring of polyp**

**रक्तदान से दूसरों की बचायी जा सकती है जिंदगी : निदेशक**

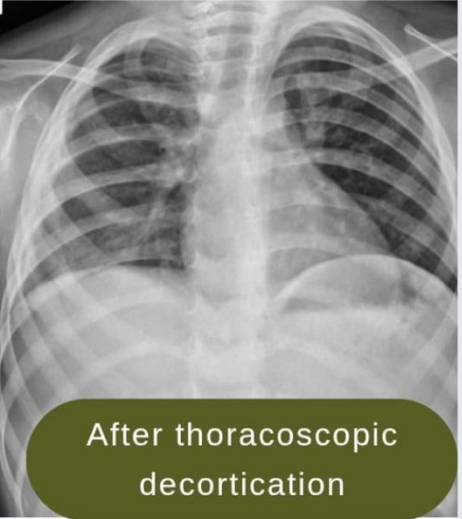

**Blood donation camp**

रक्त की कमी के कारण गंभीर स्वास्थ्य

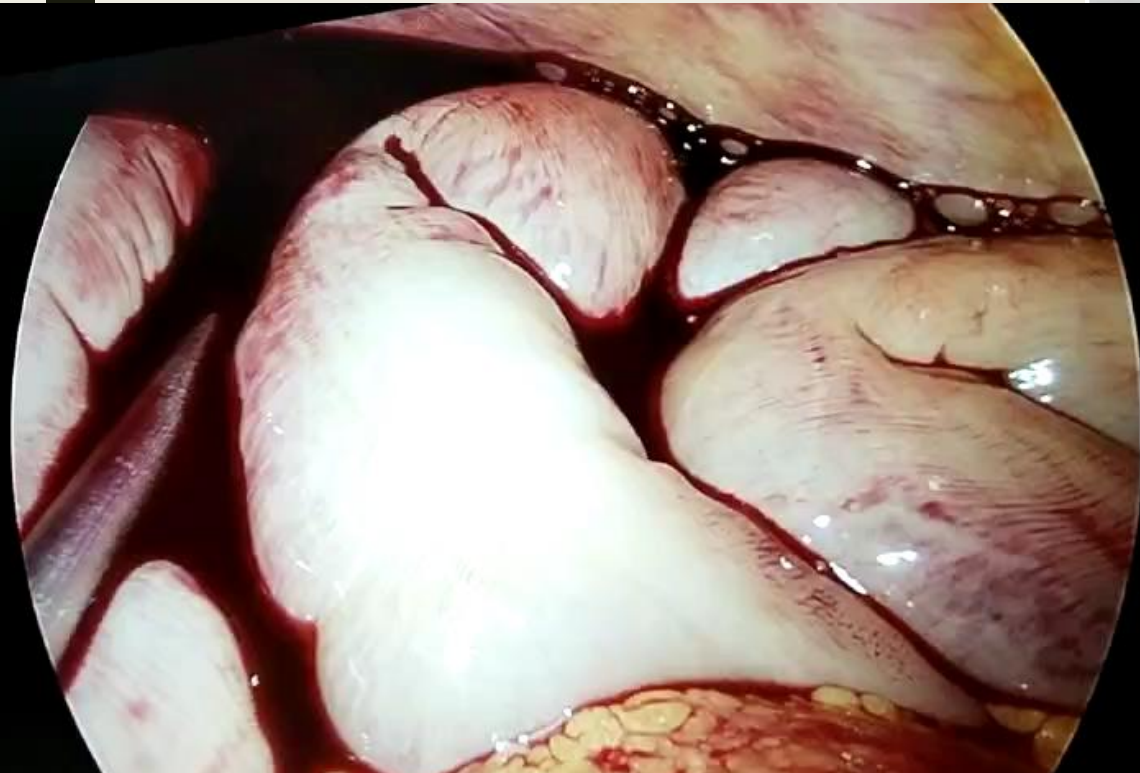
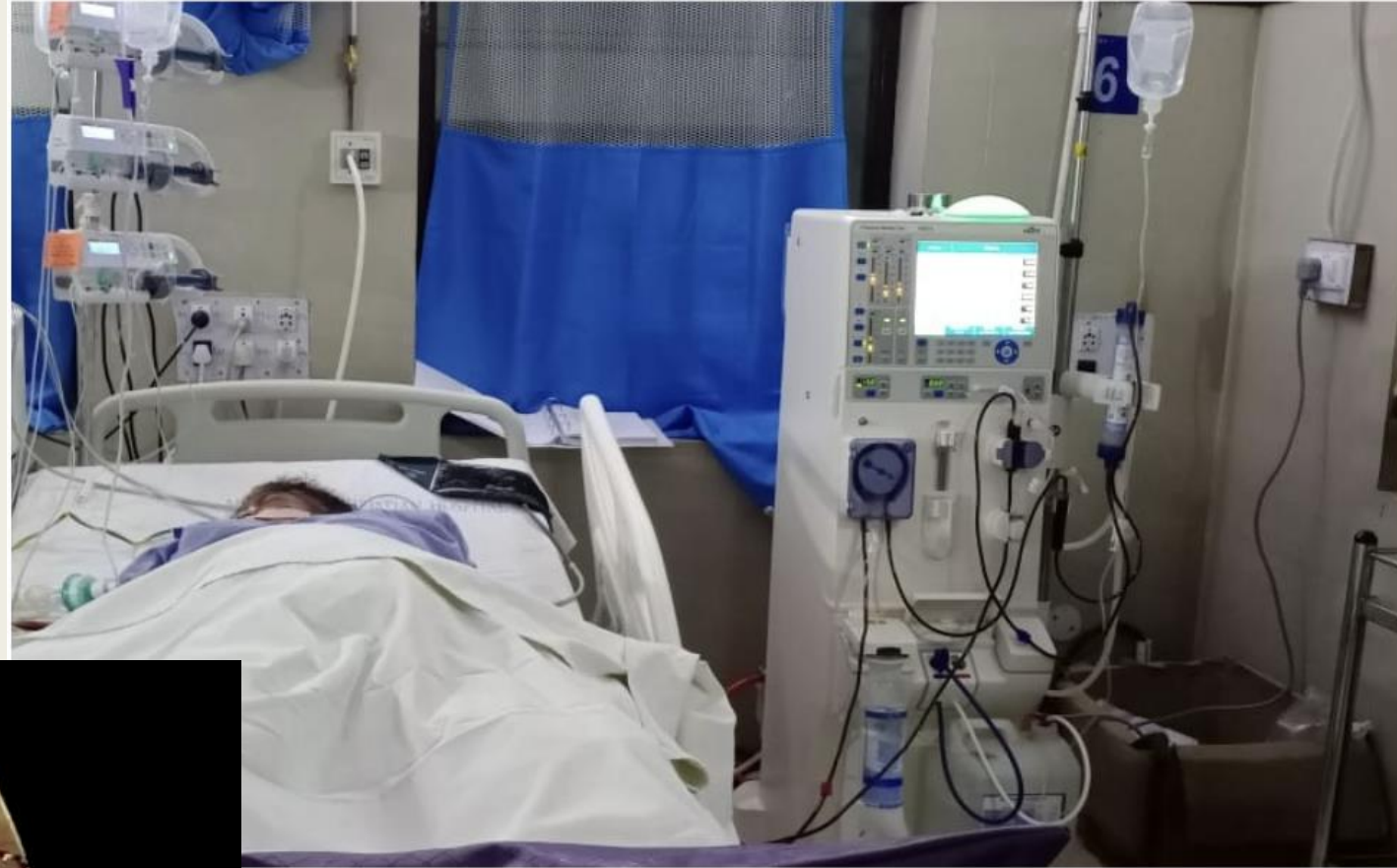
**Before surgery after 4 weeks on chest tube**



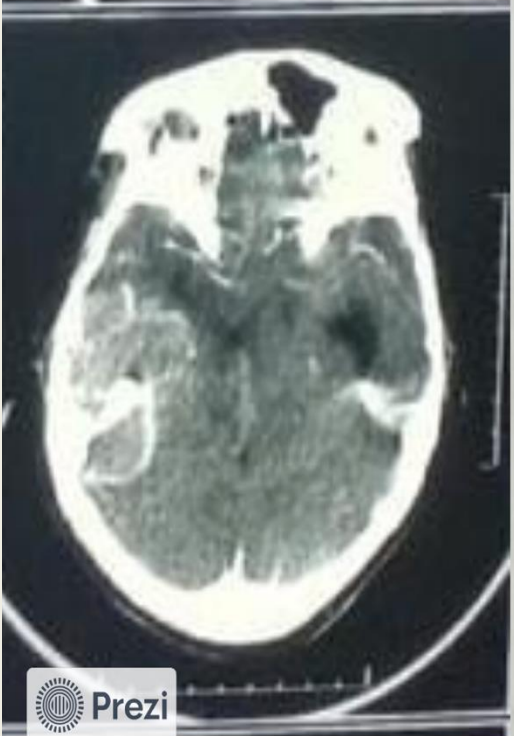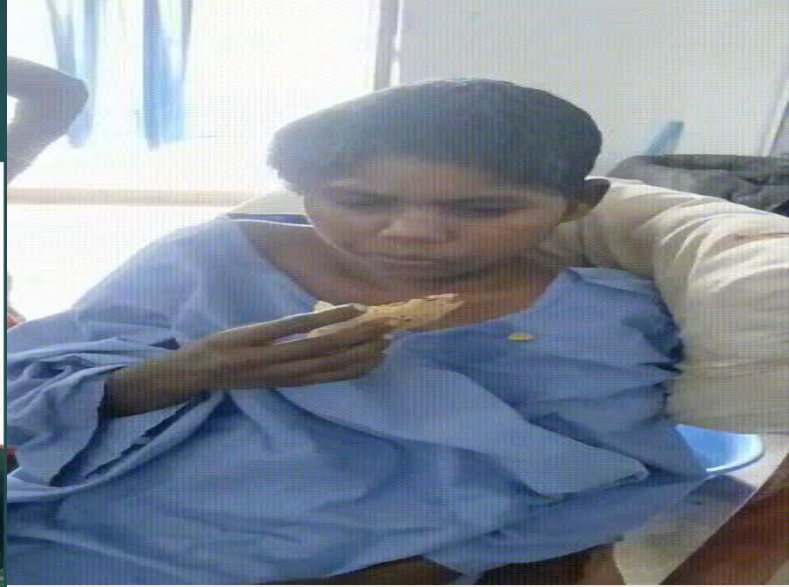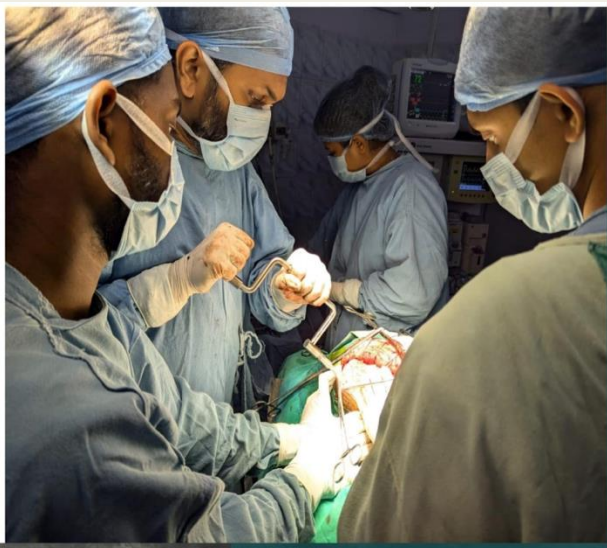**After thoracoscopic decortication**

## **Hemodialysis**



## **Auto Transfusion**

# Care for the Forgotten




**MADHEPURA SCANNING CENTRE**  
 Add: West Bypass Road, Near Petrol Pump  
 Mob: 9570321952, 7631533900  
 E-mail: madhepura.scanning@gmail.com

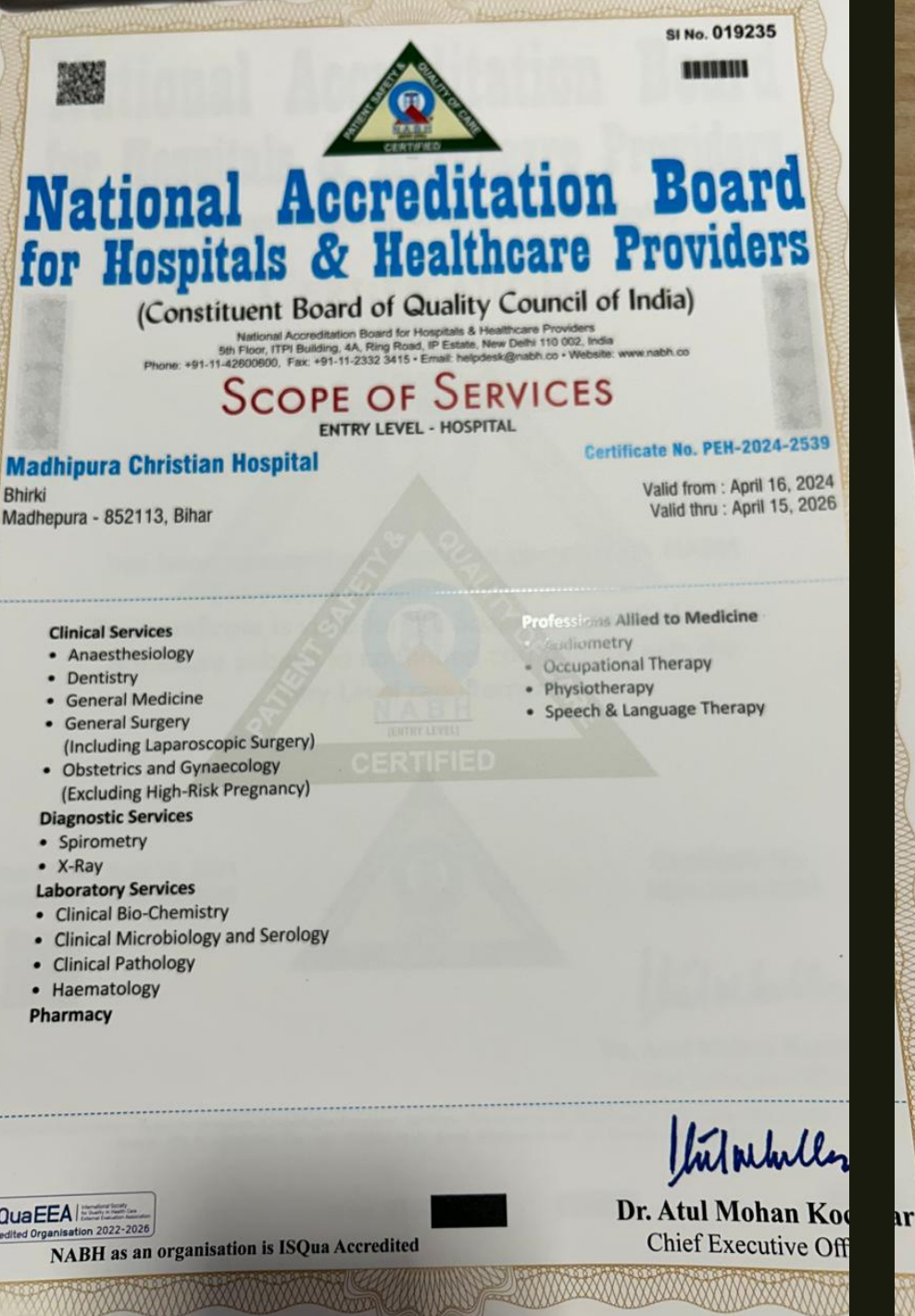
Patient Name :	KARI DEVI	Age / Gender :	25Y / F
Patient ID :	06028	Date & Time :	11-04-2025 09:43 PM
Refd By :	DR.MCH	Modality :	CT

**CT - CT HEAD CONTRAST:**  
 Large extra axial well defined, well marginated, broad base towards dura soft tissue mass lesion measuring 66 X 45 mm seen involving right temporo-parietal lobe extending to right sided basi-temporal and right posterior fossa.  
 The above mentioned lesion shows surrounding cerebral edema and causing mass effect in form of compression over right lateral ventricle and displacement towards opposite side measuring 16 mm, causing compression over 3rd ventricle resultant causing dilatation of right lateral ventricle... ?? Obstructive hydrocephalus.  
 On post contrast study, The lesion shows internal homogenous enhancement.  
 ... Above findings suggests possibility of Extra axial neoplastic etiology- Meningioma more likely. ADV: MRI for further evaluation.  
 Sulci both cerebral Hemisphere shows contrast enhancement s/o meningitis more likely. Sella and pituitary are normal. Parasellar structures are unremarkable.  
 The paranasal sinuses and mastoid air cells are normally developed, clear and pneumatized.  
 The orbital contents are unremarkable.  
 There are no abnormalities in the calvarium.  
 No evidence of any obvious fracture seen.  
 No evidence of extra-axial collection.  
 No evidence of any hemorrhage

**IMPRESSION**  
 ... Above findings suggests possibility of Extra axial neoplastic etiology- Meningioma as described above. ADV: MRI for further evaluation.  
 Changes of meningitis more likely.  
 Please correlate clinically.

*Megha*  
 Dr. Megha Damor  
 MBBS, MD (Radio-Diagnosis)  
 Consultant Radiologist  
 Registration No- PG/G-38830



## Standard of Care



## Patient centric standards

- Access assessment and continuity of care
- Care of patients
- Patient rights and education
- Infection prevention and control
- Patient safety and quality improvement
- Facility management and safety



**CARE**

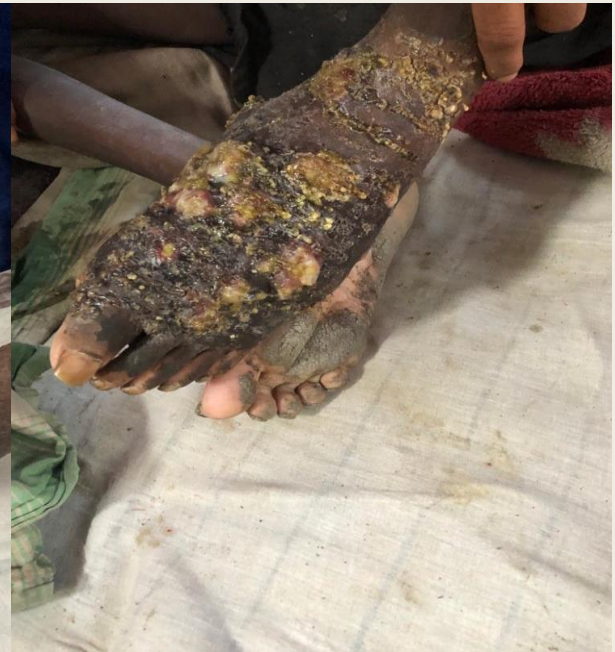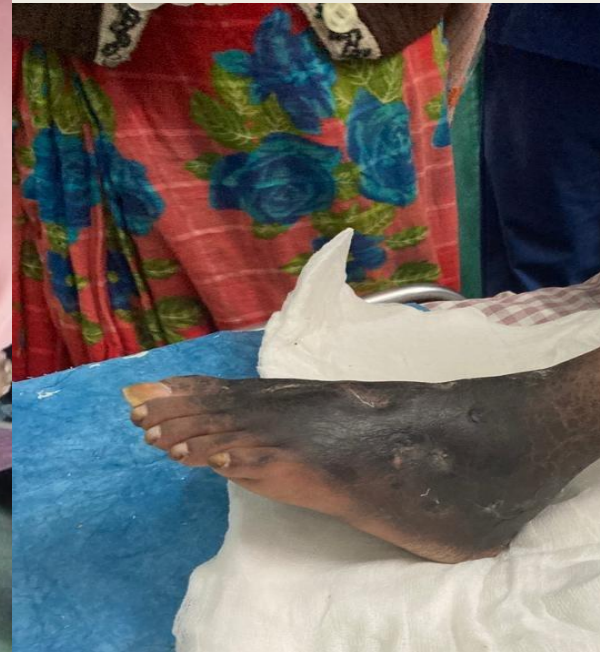**CURE**

- Community Beyond Hospital– The Sustainability Struggle
- Care Over Cost – Thriving In The Survival Mode
- Care beyond Caste – Integrated model: HEAL Madhepura
- Community Based Care
- Care combining Technology
- Care for the Caregiver

# COMMUNITY BEYOND HOSPITAL

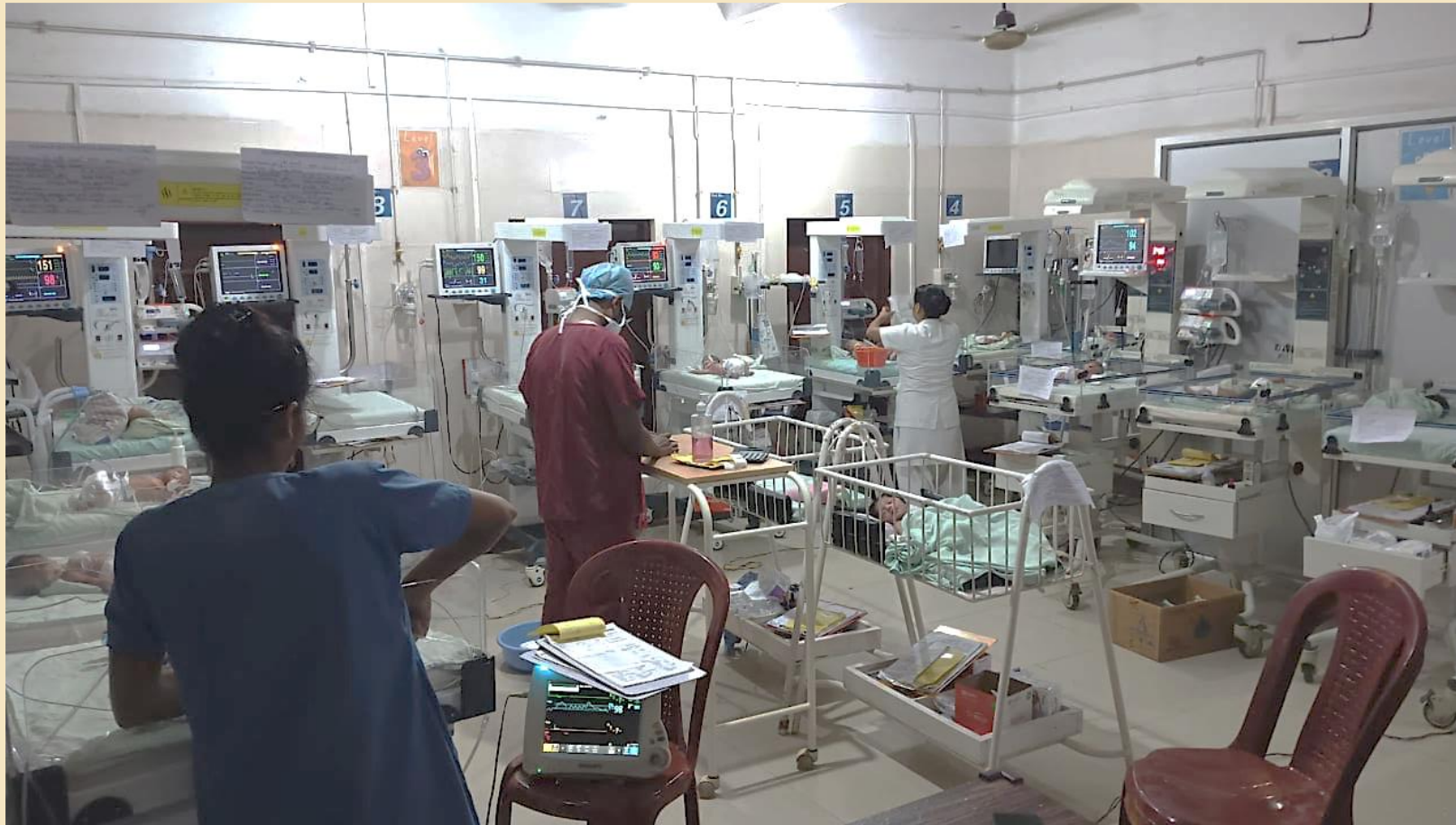- ❖ Patient care is a compliance in a Hospital
- ❖ Patient care for the poor is the mandate in a Mission Hospital
- ❖ No income generation
- ❖ Just an investment with dividends

The Hospital Exists For The Community;  
The Community Lives In Health Because Of  
The Hospital



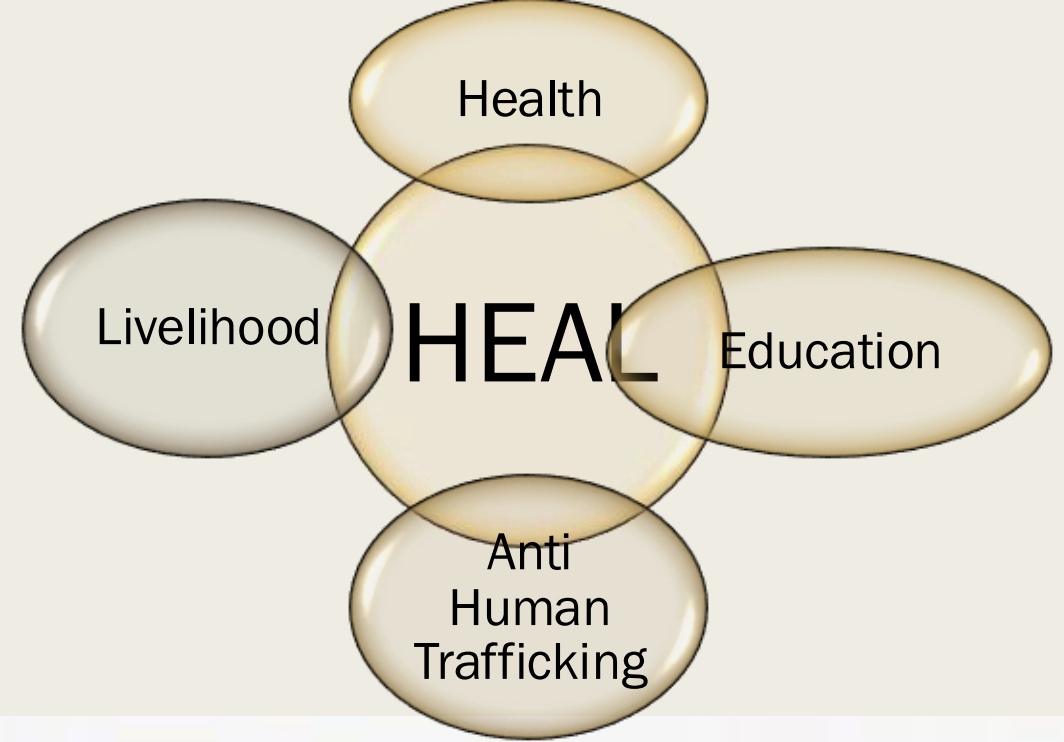
# CARE OVER COST – MISSION OVER SUSTAINIBILITY

- ❖ Cure can be a luxury
- ❖ Care is for all
- ❖ MCH – The Deal and Subsidized treatment over sustained period
- ❖ Makunda Model – No private rooms, only general ward



# CARE BEYOND CASTE

## HEAL MADHEPURA



# CARE FOR THE CAREGIVER – MEMBER CARE



@rajeevranjan551

49.8k views



मधेपुरा: मुरलीगंज थाना क्षेत्र के जोलारही गांव में मेंटल पति ने दबिया से हमला कर तीन महिला को किया जख्मी, सदर अस्पताल में भर्ती

Madhepura, Madhepura | May 14, 2021

## Beauty in Brokenness



Jesus asked Peter  
“Do you love me ?”

Then take care of my sheep, He  
said.

