


# Vascular Access: Methods, Tips, and Tricks


**Nick Maxwell MD**  
**Jessica Pelletier DO**

 Washington University in St. Louis  
SCHOOL OF MEDICINE

1

## Disclosures


- No relevant financial relationships with ineligible companies to disclose

 Washington University School of Medicine in St. Louis Department of Emergency Medicine  
Division

2

## Options for Vascular Access


- Standard peripheral IV
- EJ
- IO
- US guided peripheral IV
- Easy IJ
- Central line

 Washington University School of Medicine in St. Louis Department of Emergency Medicine  
Division

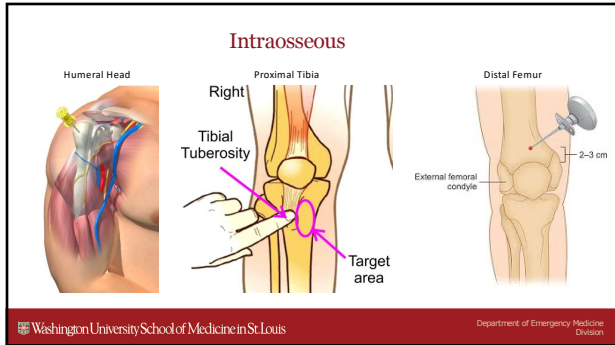
3

## Intraosseous

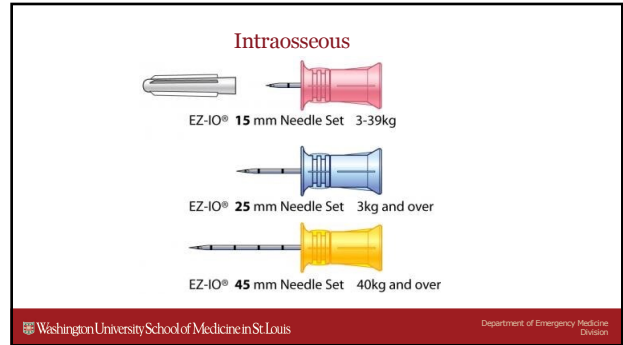
- Site choices
- Site selection
- Size selection
- Technique

 Washington University School of Medicine in St. Louis Department of Emergency Medicine  
Division

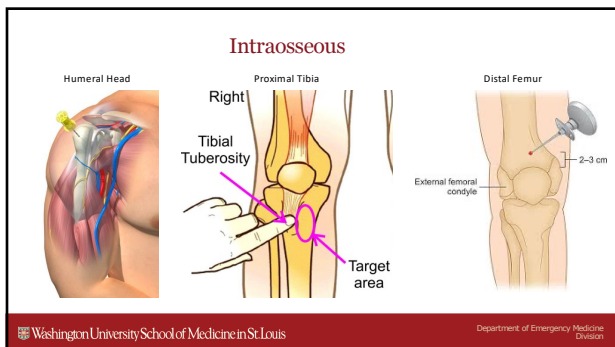
4



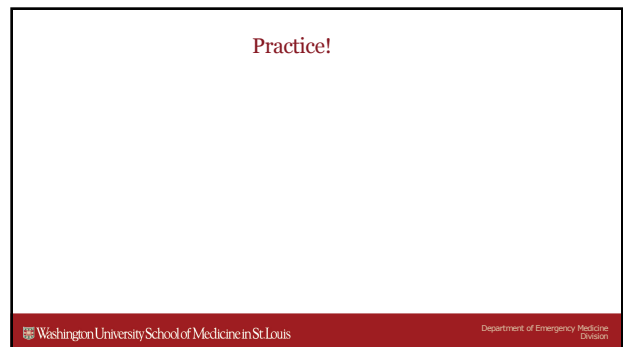
5



6



7



8

### US Guided IV

- Supplies
- Site selection
- Positioning
- Placement
- Confirmation

Washington University School of Medicine in St. Louis Department of Emergency Medicine Division

9

### US Guided IV - Supplies

- IV
- US gel
- Probe cover
- IV start kit

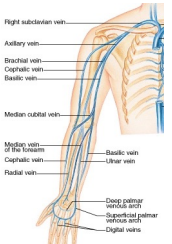


Washington University School of Medicine in St. Louis Department of Emergency Medicine Division

10

### US Guided IV – Site Selection

- Vein size
- Vein depth
- Confirm it's a vein
- Good trajectory
- Good approach



Washington University School of Medicine in St. Louis Department of Emergency Medicine Division

11

### US Guided IV - Placement

- Position and coach the patient
- “Big poke” - often steep angle
- Find needle tip
- Advance probe, advance needle, NOT BOTH
- Access vein, continue up vein

Washington University School of Medicine in St. Louis Department of Emergency Medicine Division

12

### US Guided IV – Placement Trouble Shooting

- Adjust gain – usually down
- If lost, move probe to needle base
- Wiggle needle tip
- Beware of fuzzy tip in vessel
- Watch out for the bed and tourniquet

Washington University School of Medicine in St. Louis Department of Emergency Medicine Division

13

### US Guided IV - Confirmation

- Flushes easily
- No pain
- No infiltration
- Visualize catheter on US
- Visualize flush on US

Washington University School of Medicine in St. Louis Department of Emergency Medicine Division

14

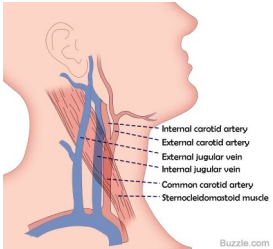
Practice!

Washington University School of Medicine in St. Louis Department of Emergency Medicine Division

15

### External Jugular and “Easy IJ”

- Turn head slightly
- Trendelenburg
- Coach patient
- Big poke



Internal carotid artery  
External carotid artery  
External jugular vein  
Internal jugular vein  
Common carotid artery  
Sternocleidomastoid muscle

Buzzle.com

Washington University School of Medicine in St. Louis Department of Emergency Medicine Division

16

