

INMED-May 2026:

POCUS & the Clinical Exam for Hypoxic Evals

**The Clinical Exam Integrated with
Two Straightforward POCUS
Applications**

Dale R. Agner, MD

dale.agner@gmail.com

+1.402.881.1861 WhatsApp

No Financial Disclosures



Overview: the hypoxic evaluation COPD vs CHF Exacerbations

- POCUS Probes and intro-review-overview
- Sensitivity-specificity: clinical exam & CXR
- Review cardiovascular volume overload
- POCUS for JVP & HJR (abdominojugular-reflux/AJR)
- POCUS for presence/absence of lung fluid
- Putting it all together (what I'm teaching the residents)

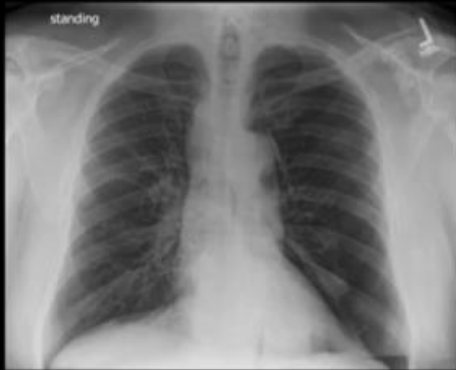Many online-free resources

*Personally, I like Dr Jared Marx, Emergency Med
University of Nebraska Medical Center (friend)*

<https://www.youtube.com/@POCUSGeek>

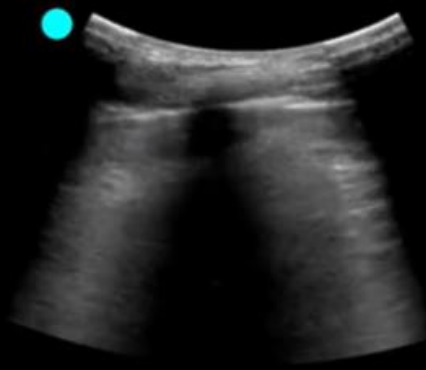
<https://spocus.org/FOAMED> (another great resource)

Chest X-ray



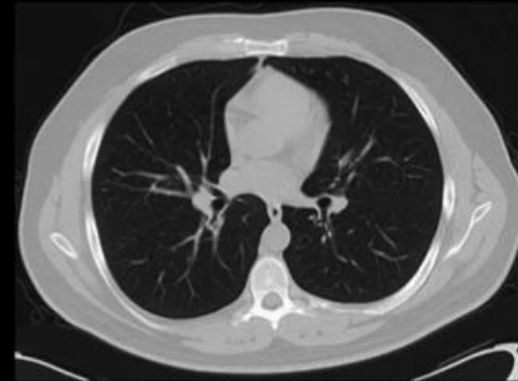
Ok

Ultrasound



Better

CT



Best

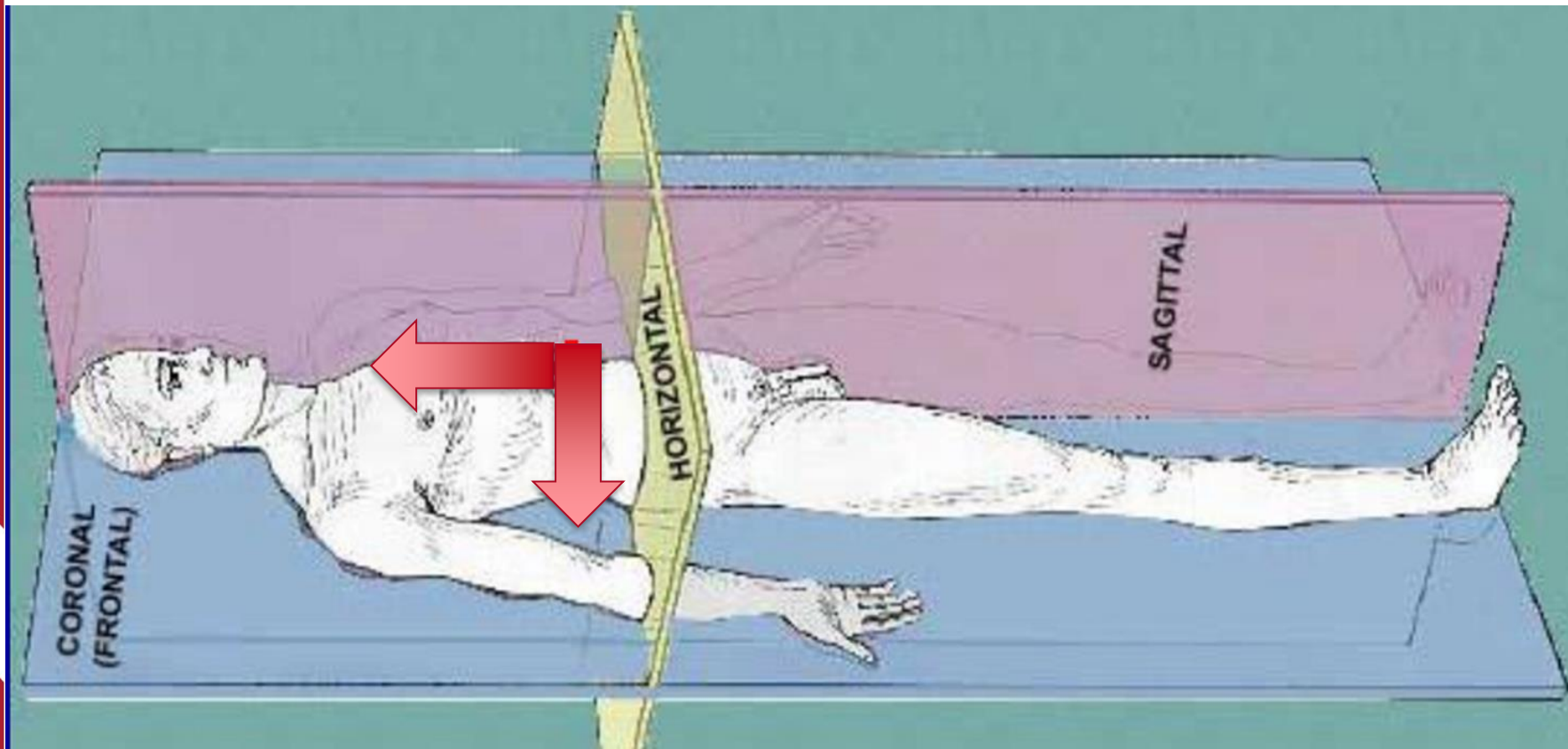
Resources for Learning Point-of-Care Ultrasonography

Resource	Cost	Comments
5 Min Sono http://5minsono.com/	Free	Collection of short videos demonstrating examinations; podcast
American College of Emergency Physicians Sonoguide https://www.acep.org/sonoguide/introduction.html	Free	Web-based curriculum of test-based descriptions with photos and videos; referenced by Ultrasound Ninja curriculum
American Institute of Ultrasound in Medicine https://www.aium.org	Prices vary by course and continuing medical education credits	Collection of continuing medical education materials for ultrasound certification; credentialing program recommending 50 credits in each body area
European Society of Musculoskeletal Radiology https://www.essr.org	Free	Webinars for radiology topics; not focused solely on ultrasonography
Massachusetts General Hospital Emergency Ultrasound Educational Website https://sites.google.com/site/mghedus/home	Free	Free video tutorials on emergency ultrasound topics
Point-of-Care Ultrasound Certification Academy https://pocus.org/	\$125 for fundamental certification, \$150 for each of 10 clinical area certificates, \$625 for emergency medicine certification with seven clinical areas	Certification programs including examination and certificate
Society for Academic Emergency Medicine https://www.saem.org/education/saem-online-academic-resources/topics/ultrasound	Varies by membership level	Faculty performing and teaching emergency ultrasonography; includes modules for physicians at different levels of experience
SonoSpot: Topics in Bedside Ultrasound http://sonospot.com/	Free	Tutorials with verbal descriptions for probe placements and photos; short videos of ultrasound images showing expected results
Ultrasound Ninja http://www.ultrasoundninja.com/	Free	Emergency medicine ultrasound program; curriculum consisting of podcasts and references for each curricular element; free e-book
Virtual Transthoracic Echocardiography Website http://pie.med.utoronto.ca/TTE/index.htm	Free	Tutorial for performing transthoracic echocardiography

Probe Orientation (determine the “notch”)

Generally speaking, orient the probe to either:
9 O'clock (Pt's right) or
12 O'clock (Pt's head)

Probe motions: Slide, Rock, Rotate, Fan



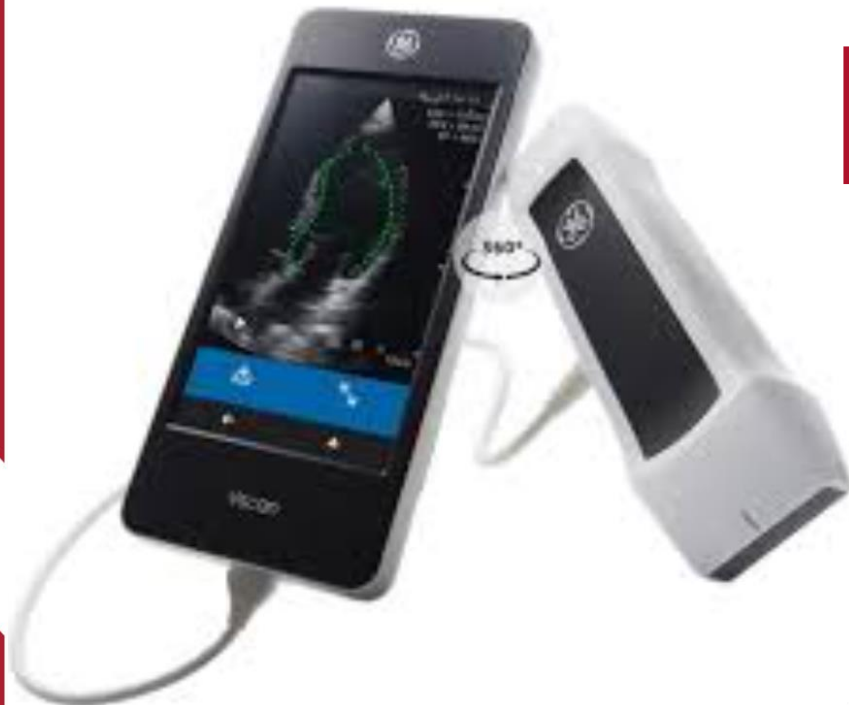Key Learning Points

- ~30 of acute left heart failure wheezes
- ~20% of acute left ventricular acute heart failure will **not have appreciable lower extremity edema²**
- **Acute HFpEF often WON'T HAVE** elevated **JVP** but **WILL HAVE** elevated **AJR-HJR** 😊
- But heart failure (HF) will be positive for:
 - **Expiration generally not prolonged**
 - **Positive AJR-HJR >3cm (*physical exam*)**
 - **Sonographic Pulmonary B-Lines**

(Point of Care Ultrasound)

**POCUS
to the**

Rescue!!!



Key Points for Today

- **This is one-part physical exam review**

Review of some things forgotten or not fully understood (HJR always confused me, differentiating it from JVP)

(and the pitfalls of anchoring on clinical exam features with suboptimal sensitivity-specificity)

- **Another part using POCUS** to identify the “hidden” physical exam of JVP-HJR

- **Third part** interpreting a **new application** of the POCUS for fluid in the lungs (B-lines); interpreting “Air-A lines” from

A New POCUS “Protocol” to evaluate acute hypoxia

- Something Old JVP & HJR
- Something New POCUS B-lines
- Something Borrowed POCUS HJR
(instead of IVC)
- Someone Blue
(hypoxia evals) Assess Jugular-Lung
for **exacerbations** of
COPD vs CHF vs PE

J-LuX Protocol

POCUS of **J**ugular & **L**ung for **eX**acerbations


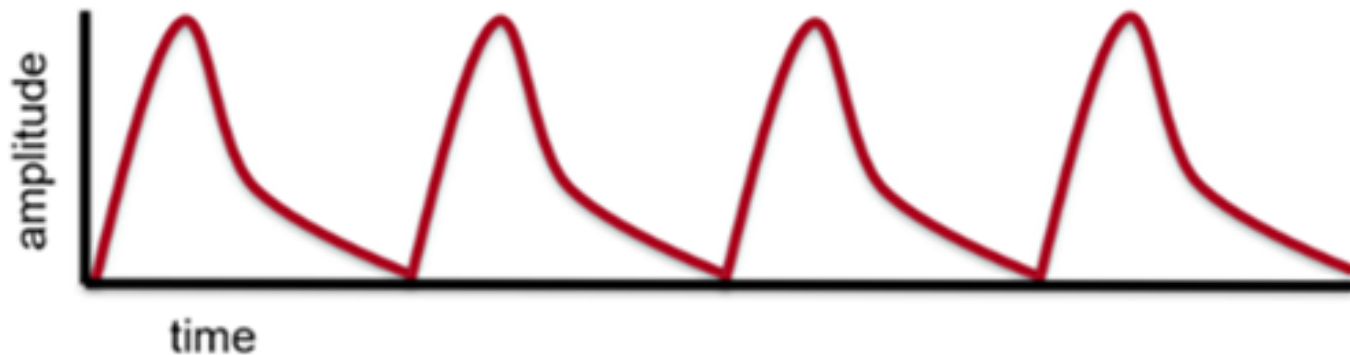
Decompensated Left Ventricular Heart Failure **WHEEZES 30% of the time**¹

- Wheezing in heart failure (HF):
 - **Expiration (length) is NOT prolonged**
 - Increased surface tension of the alveolar fluid leads to no prolongation of the expiratory phase (vs inspiration; **I:E ratio**)
- Take the time to listen-measure the length of inspiration compared to expiration
 - COPD: **prolonged** expiratory phase (compared to inspiration, by definition)
 - But ~40-50% w/CHF have COPD & those w/COPD have CHF ~20-30% of the time (I:E is not perfect, but helps)

Differentiating the cause of Wheezing between CHF & COPD (as both can wheeze)

Observe the breathing pattern

- inspiration to expiration ratios are normally ~1:1



Expiration is **prolonged** with a **COPD** exacerbation.

- **No prolongation** with **heart failure** (Insp:Exp ~1:1)
- *Even though wheezing can be heard in both scenarios!*

The Forgotten part of the Physical Exam

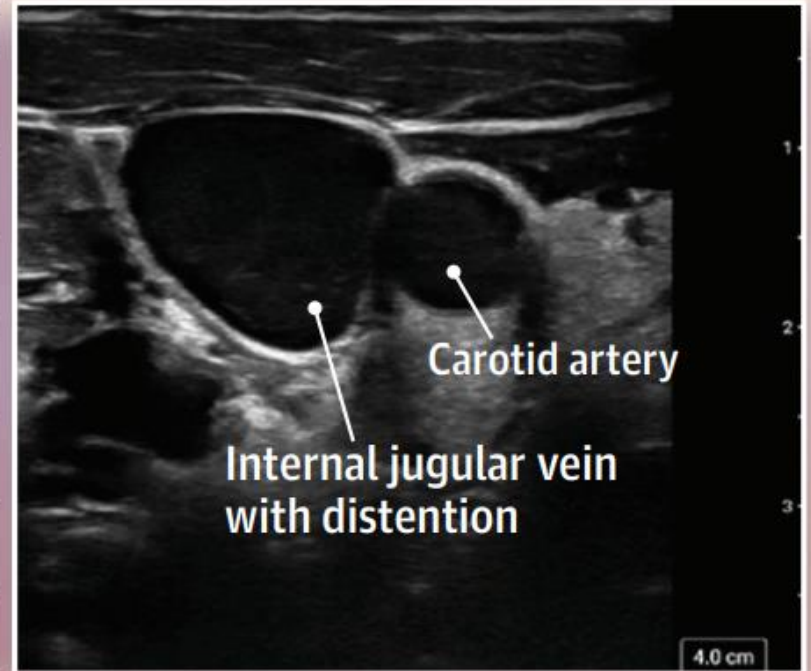
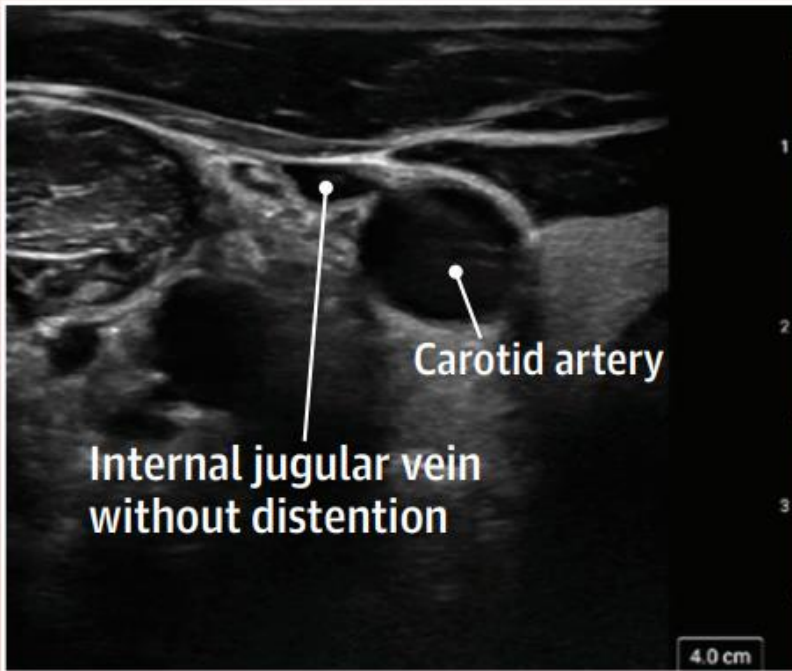
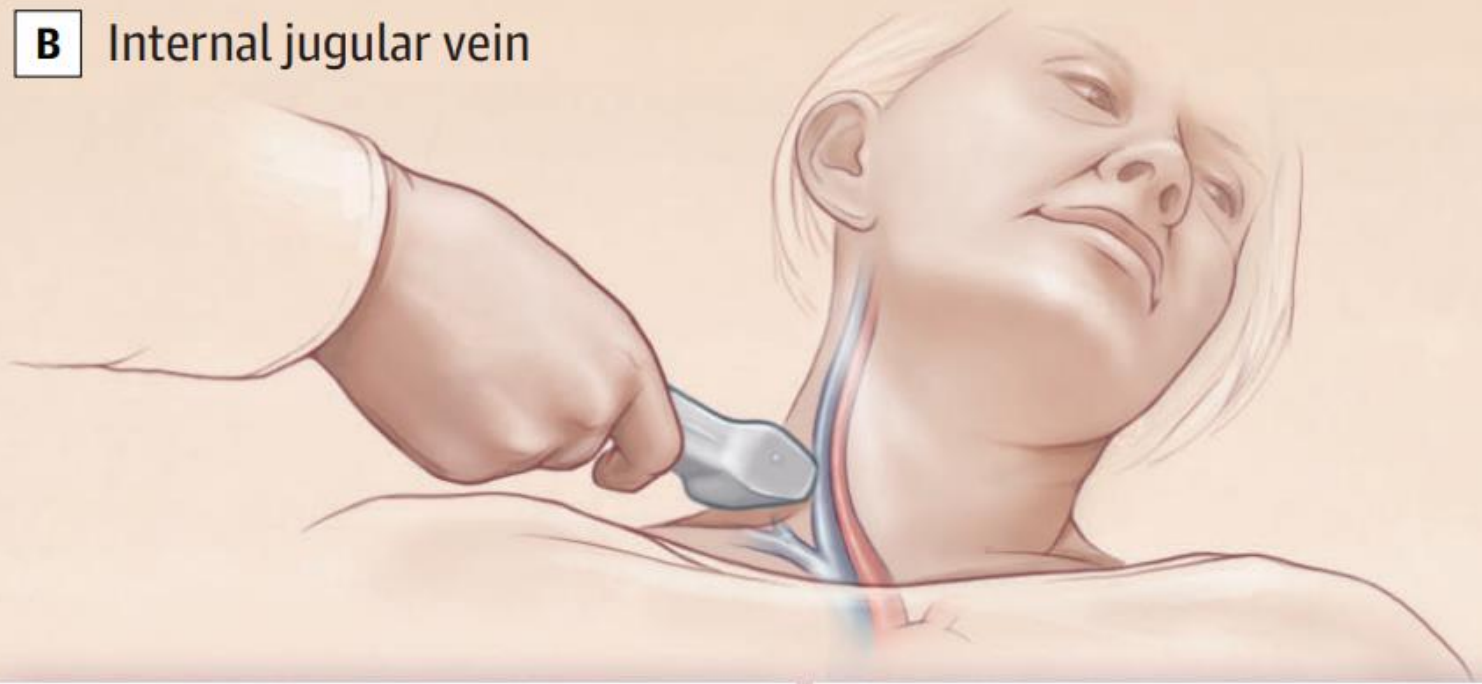
- **LUNGS (beyond abnormal sounds & flow)**
 - **HOW LONG for INSPIRATION?**
 - **HOW LONG for EXPIRATION?**
 - **What is the I:E ratio?**
 - **(augment with POCUS, B-Lines?)**
- **NECK VEINS (hard with thick necks)**
 - **Jugular Venous Pressure (right heart)**
 - **Abdominojugular Pressure (left heart)**
 - **POCUS can reliably identify**

JVP measures: **RIGHT** atrial pressure

HJR-AJR: estimation of LEFT atrium

- **Jugular Venous Pressure (JVP)** measures the **RIGHT SIDE** of the heart
- Elevated JVP:
 - Pulmonary HTN: PE, OSA, Meth-abuse
 - “Backs up” from the left side, w/low EF
- **Abdominojugular Reflux (AJR, or HJR)**
 - AJR of ≥ 3 cm above the JVP correlates by right-heart cath to ≥ 18 mm Hg Pulmonary Capillary Wedge Pressure (definition of elevated LA pressure)
- **Acute HFpEF often WON'T HAVE** elevated **JVP** but **WILL HAVE** elevated **AJR-HJR** 😊

B Internal jugular vein



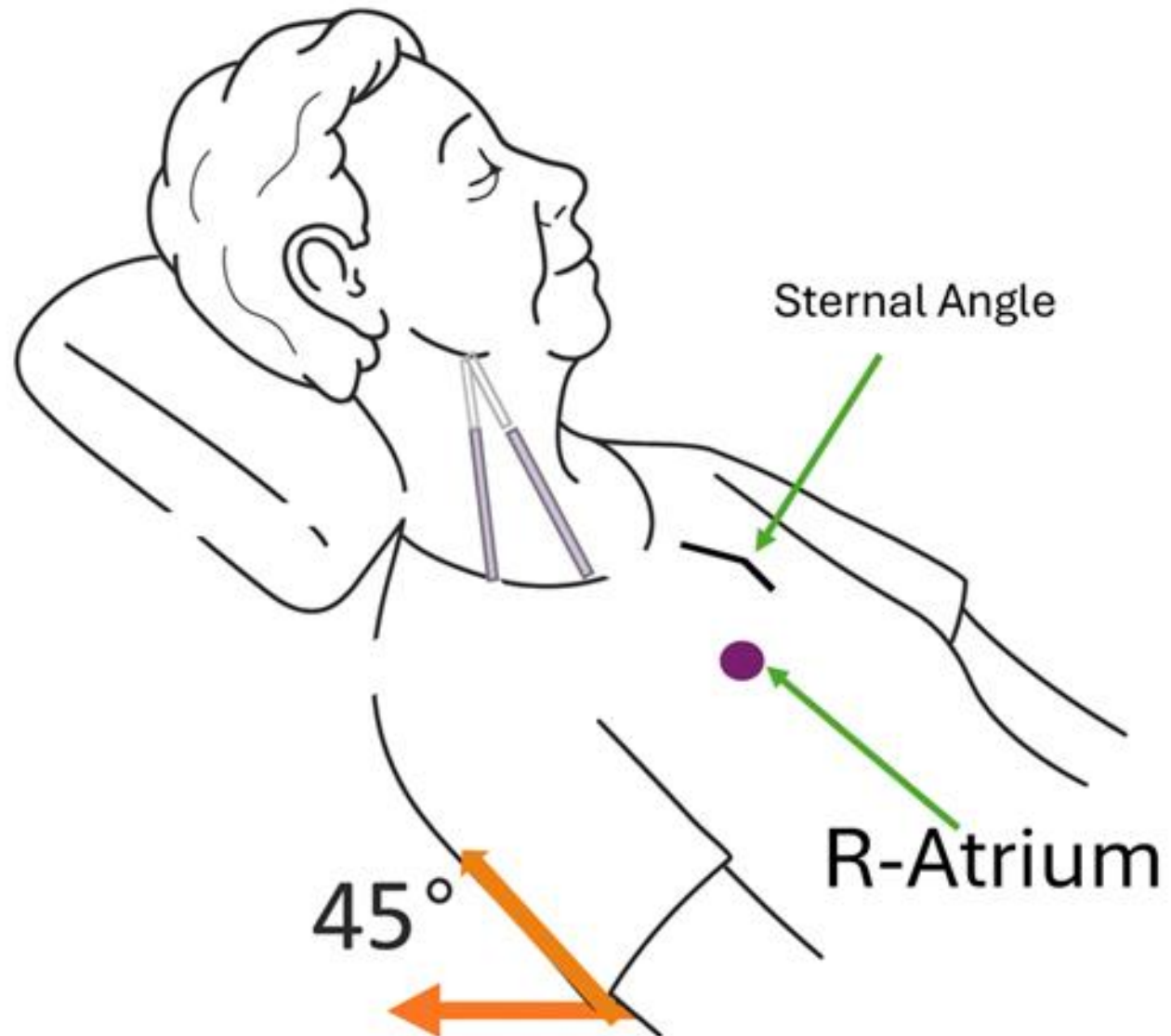
What is the Jugular Venous Pressure?

- The jugular venous pressure is the “filling pressure” within the right atrium
- “Normal Pressure” is between ~0-5 cm of water
- “Elevated Pressures usually ≥ 8 cm
- One can measure this pressure:
 - External (or internal) Jugular Veins
 - Ultrasound of the Inferior Vena Cava
 - Right Heart catheter pressure

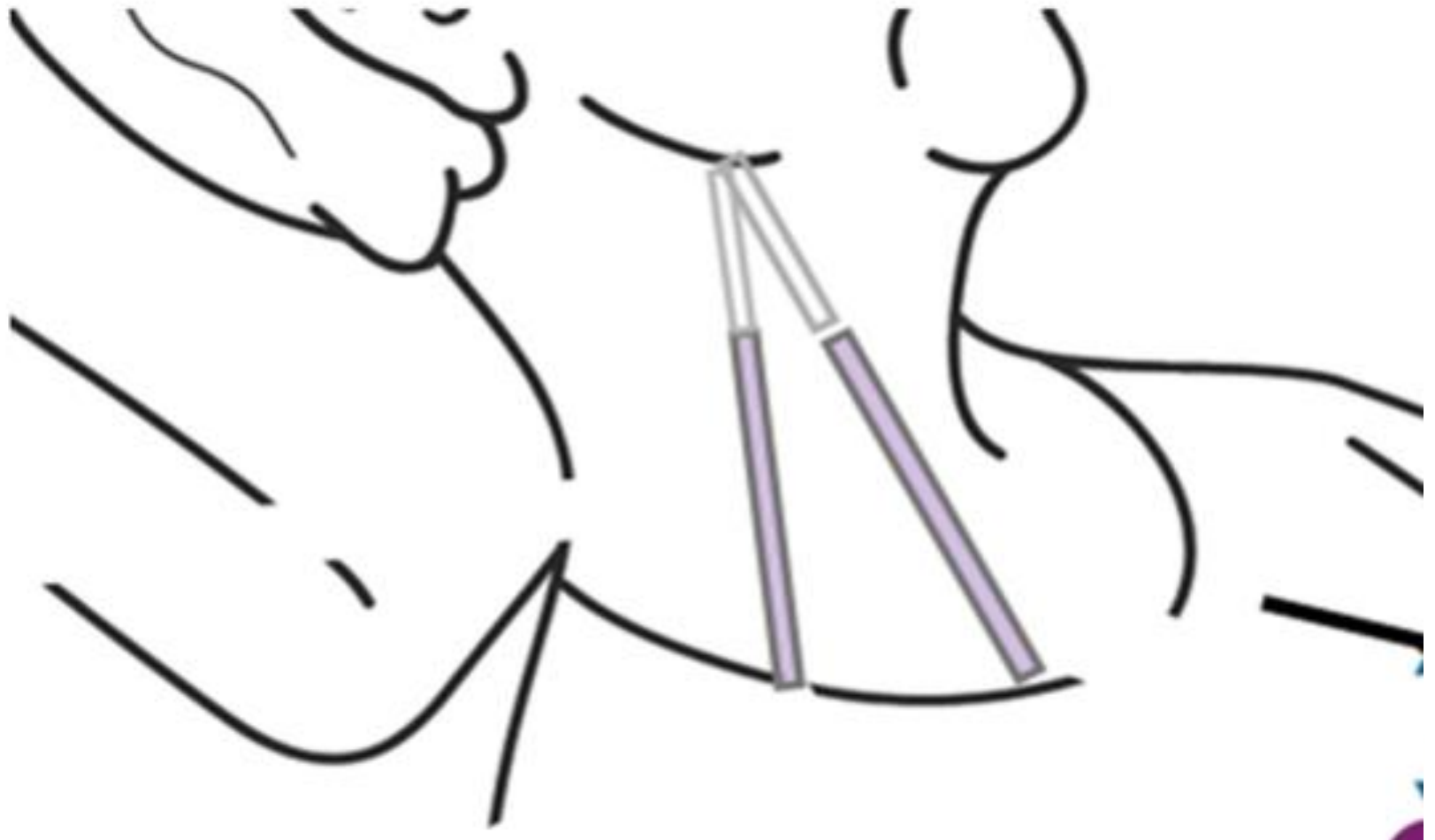Heart Failure

- With the patient at 45°
- Elevated Pressures (JVP) usually ≥ 10 cm
- 8 cm is usually at or below the clavicle
- 20 cm is usually at the angle of the jaw
- Our person is about 12-15 cm
- Can measure at 30° (describe in chart the position and height)
- One can measure this pressure:
 - External (or internal) Jugular Veins
 - Ultrasound of the Inferior Vena Cava
 - Right Heart catheter pressure

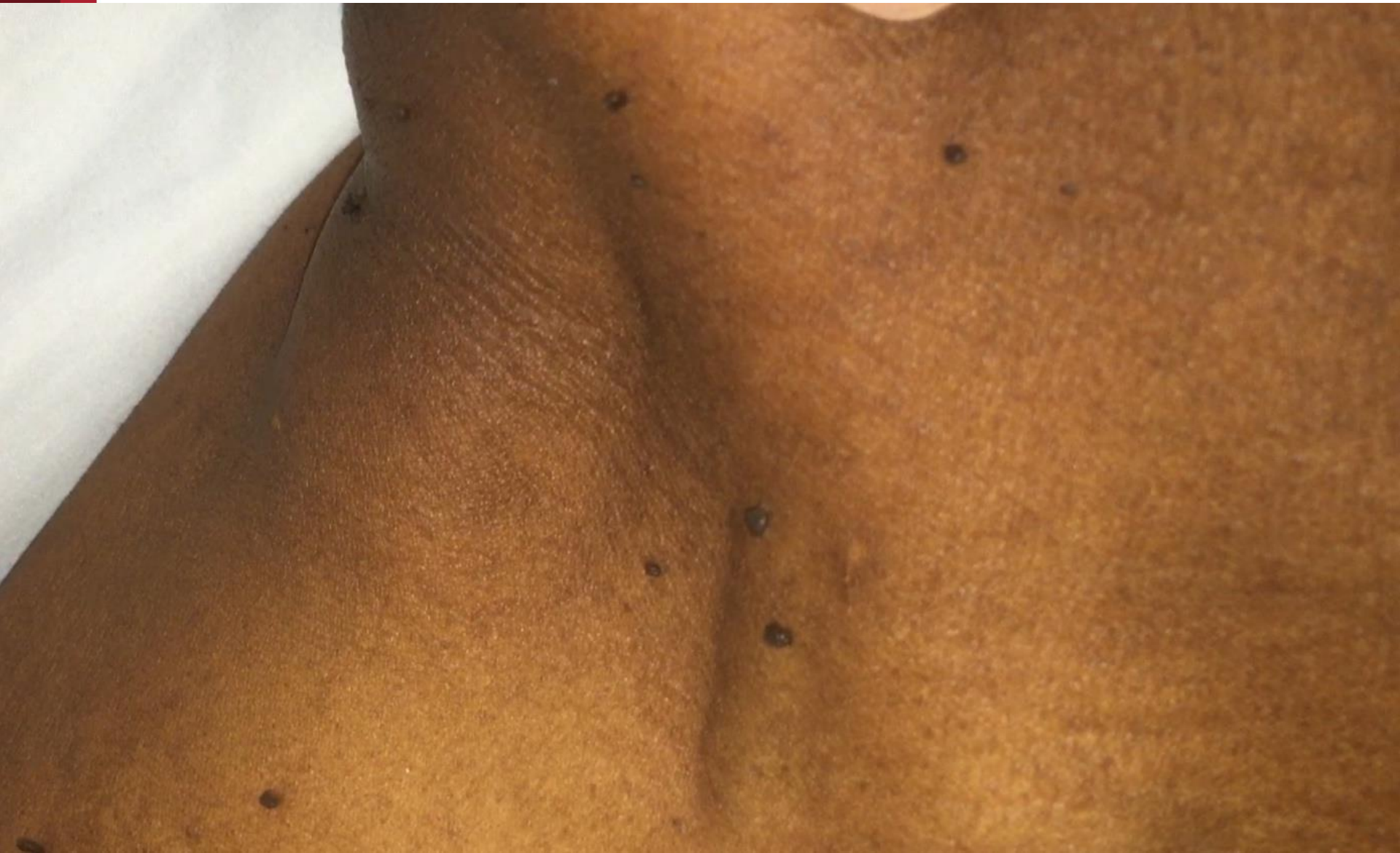Measuring the Jugular Venous Pressure (JVP)



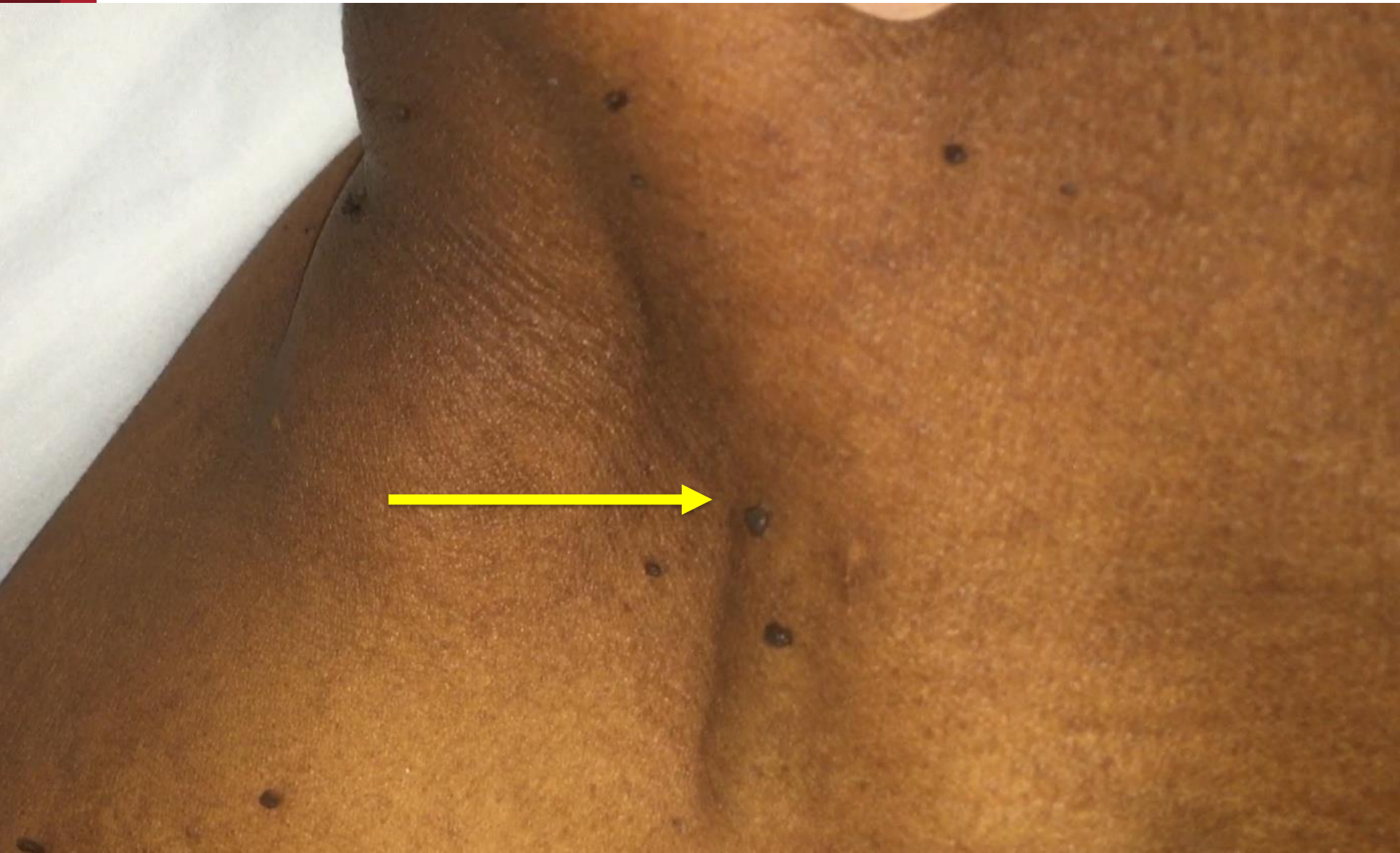Sometimes the JVP &/or HJR can be seen even with large necks



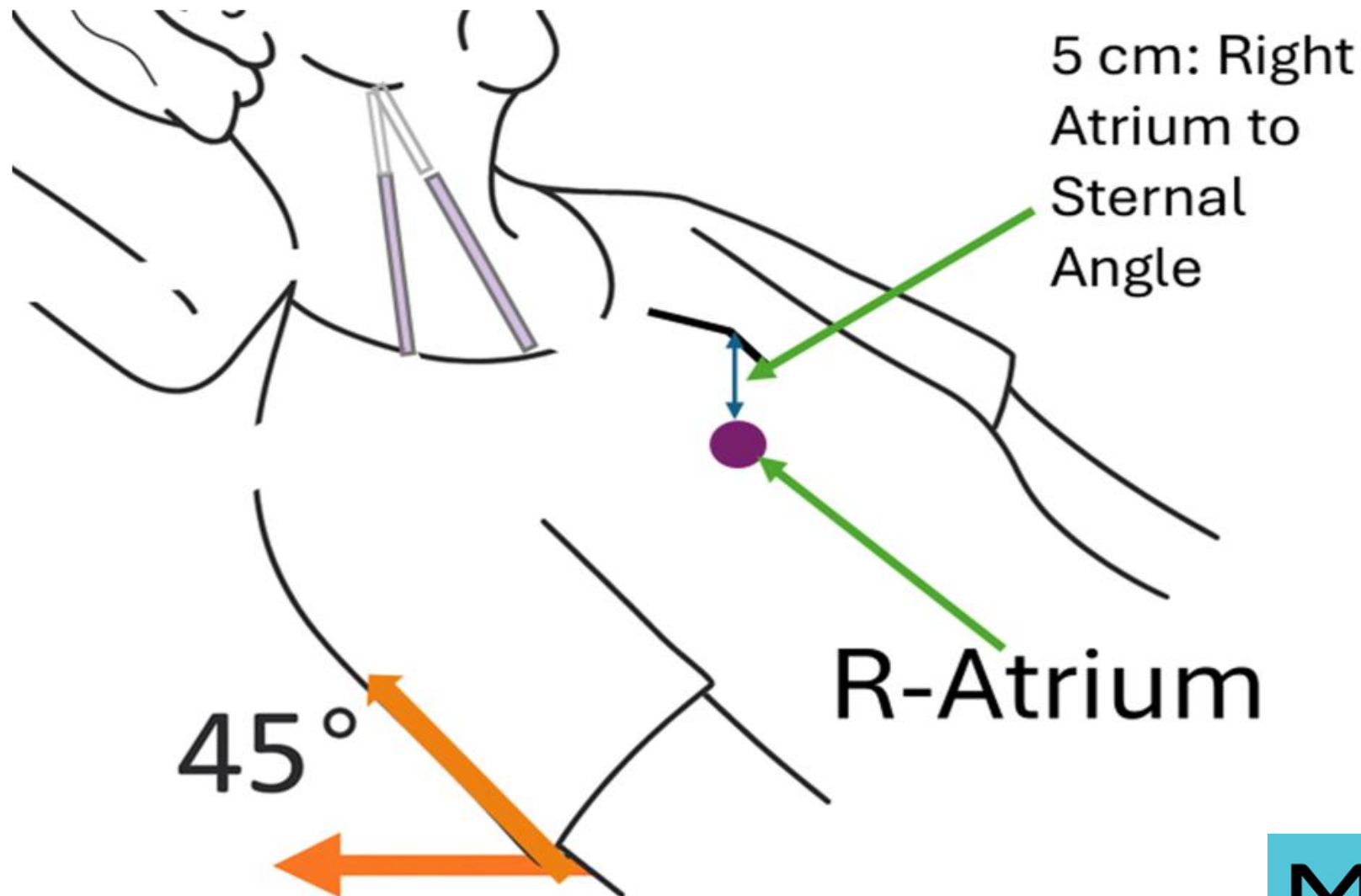
External Jugular



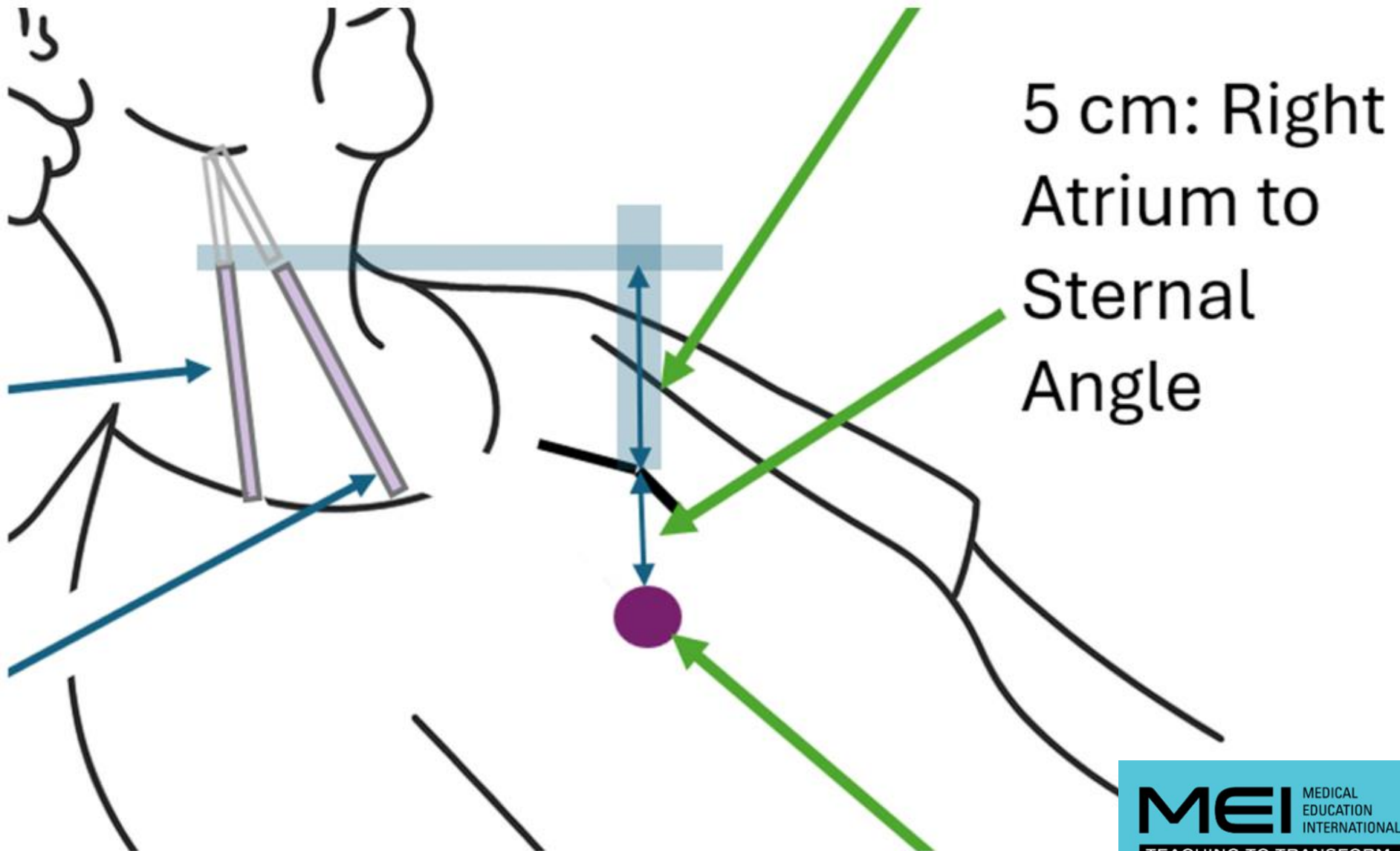
External Jugular



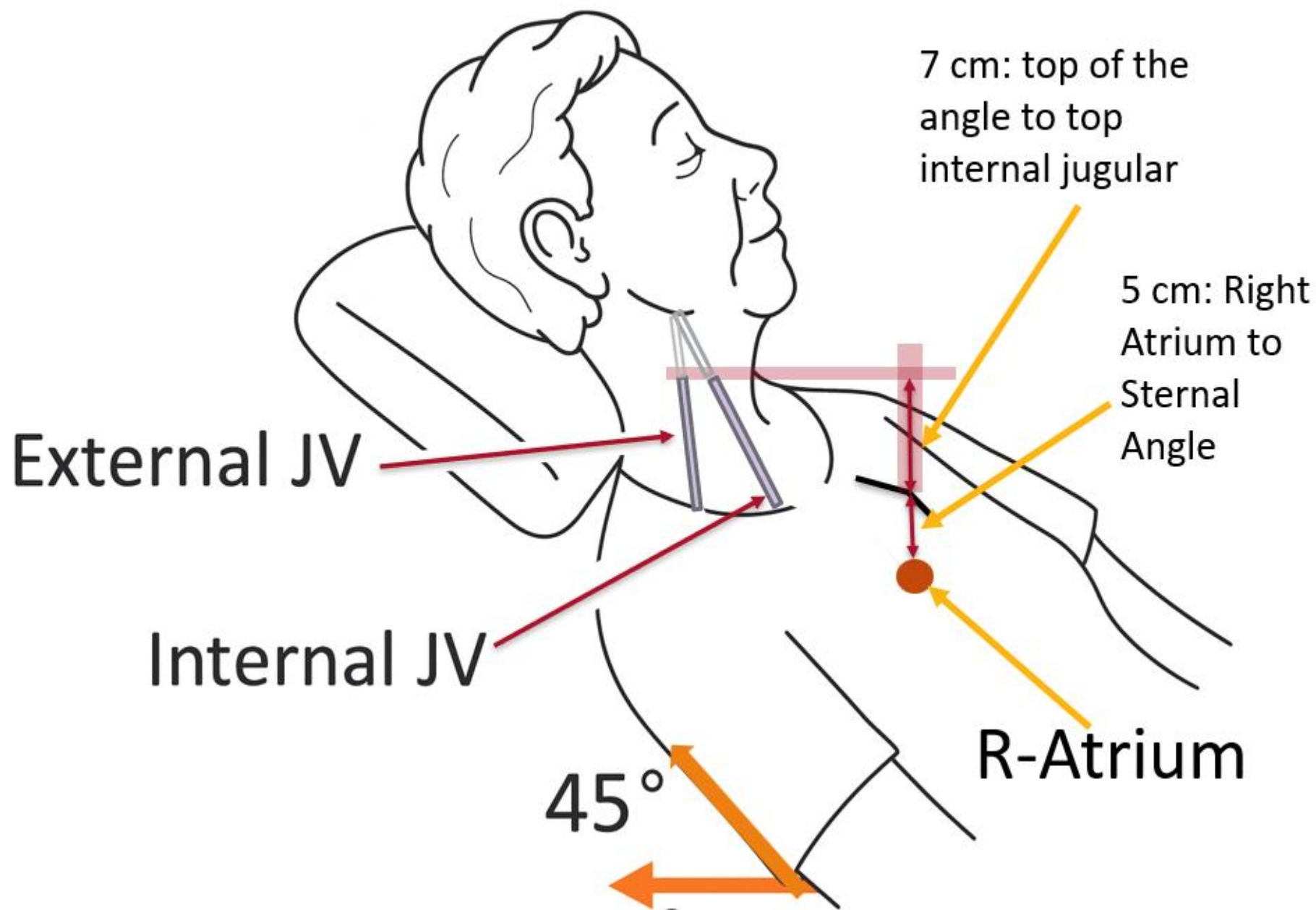
By Definition, it is 5 cm from the RA to Sternal Angle



Additional 7 cm to the TOP of the jugular vein/s



Jugular Venous Pressure: 12 cm (7 cm + 5 cm)



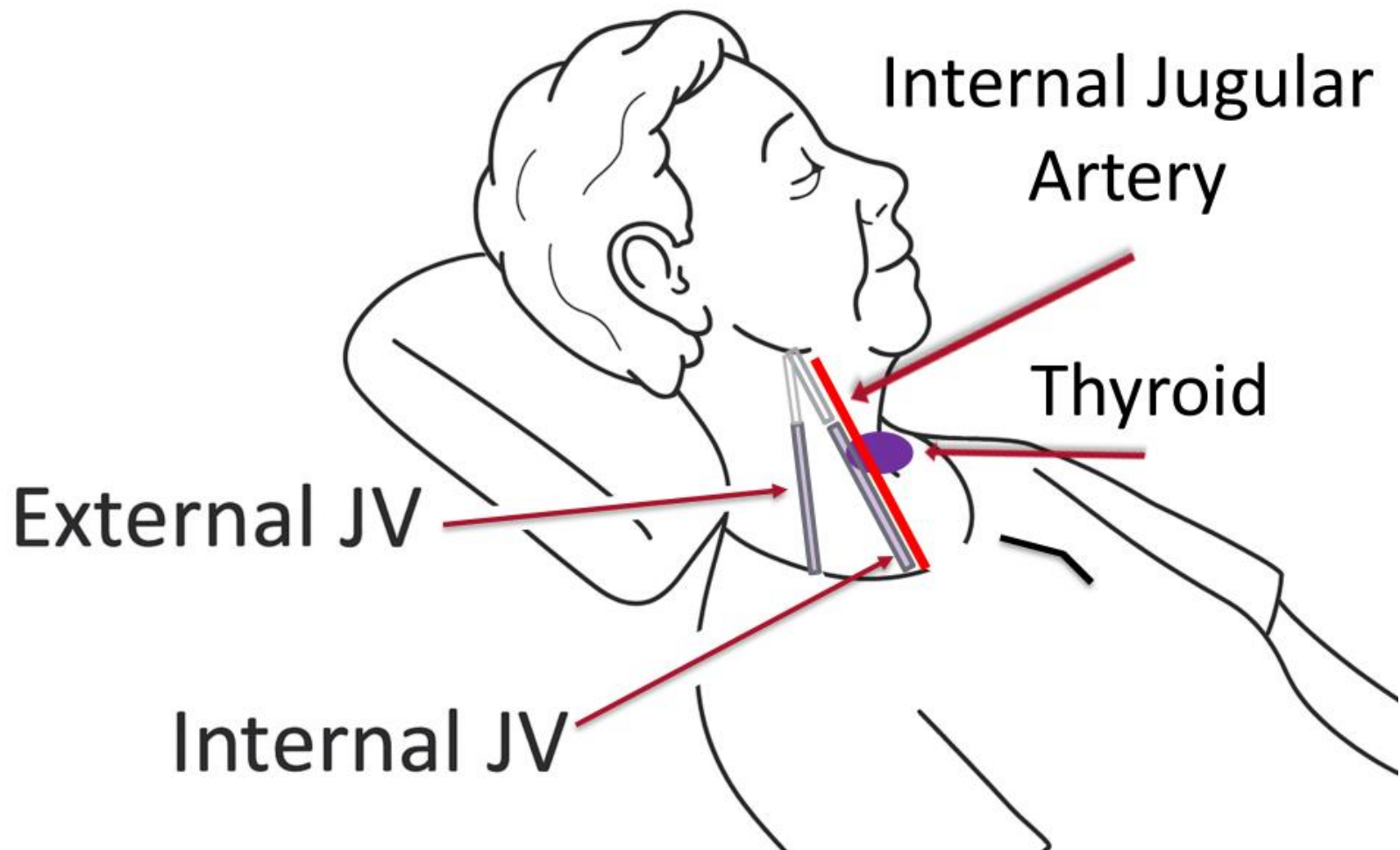
Hepato-Jugular Reflux (abdomeno-jugular reflux)

- HJR: measure of the LEFT VENTRICLE
 - Indirect measure of the Pulmonary Capillary Wedge Pressure or Left Atrium
 - Mechanism is of debate
- SUSTAINED 5-10kg (3-4 cm) subcostal pressure, for at least 10-15 seconds
- Measure the same way as the JVP
- One waits to see if there is a rise ABOVE the JVP of ≥ 3 cm, sustained, not transitory
- Acute HFpEF: can have normal JVP and by definition normal EF, but (+)AJR-HJR

The Problem

- **OBESITY brings challenges** to the physical
- **No one test is 100% Specific**
- **No test is 100% Sensitive**
- Lung sounds can mislead
- Neck veins are not really taught
- Chest Imaging can be incomplete or misleading
- Blood tests commonly have “false” normals
- There is much more to heart failure than dependent edema

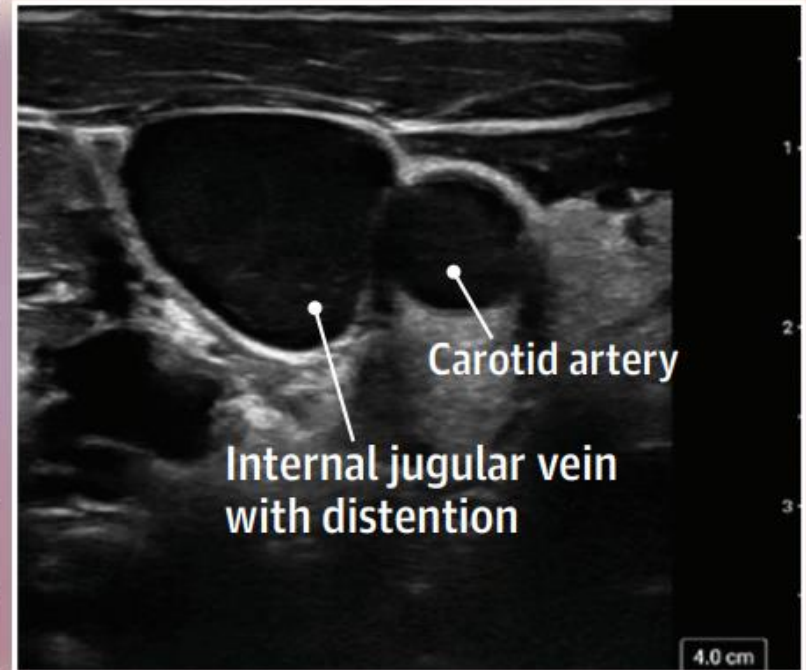
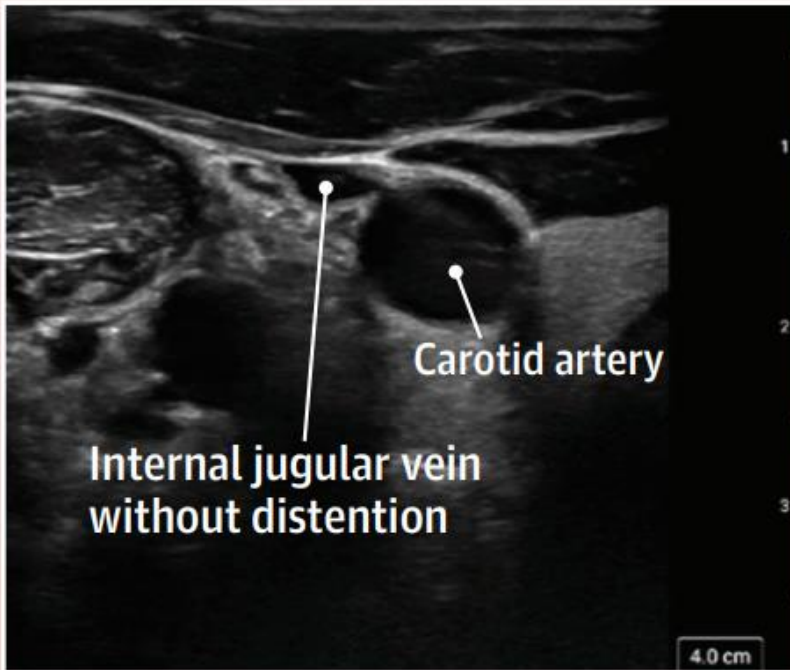
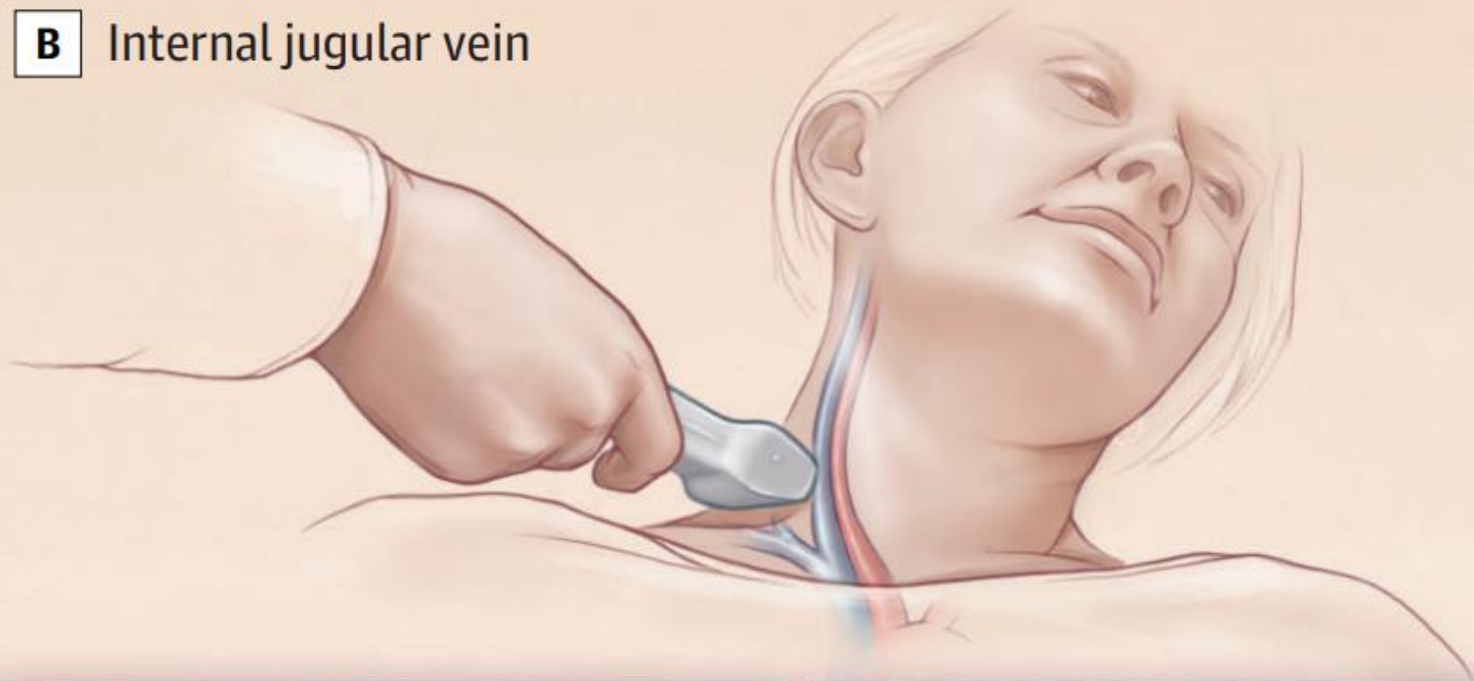
POCUS can easily identify the Thyroid, Internal Carotid & Internal Jugular Vein



Measuring the JVP and AJR-HJR by POCUS

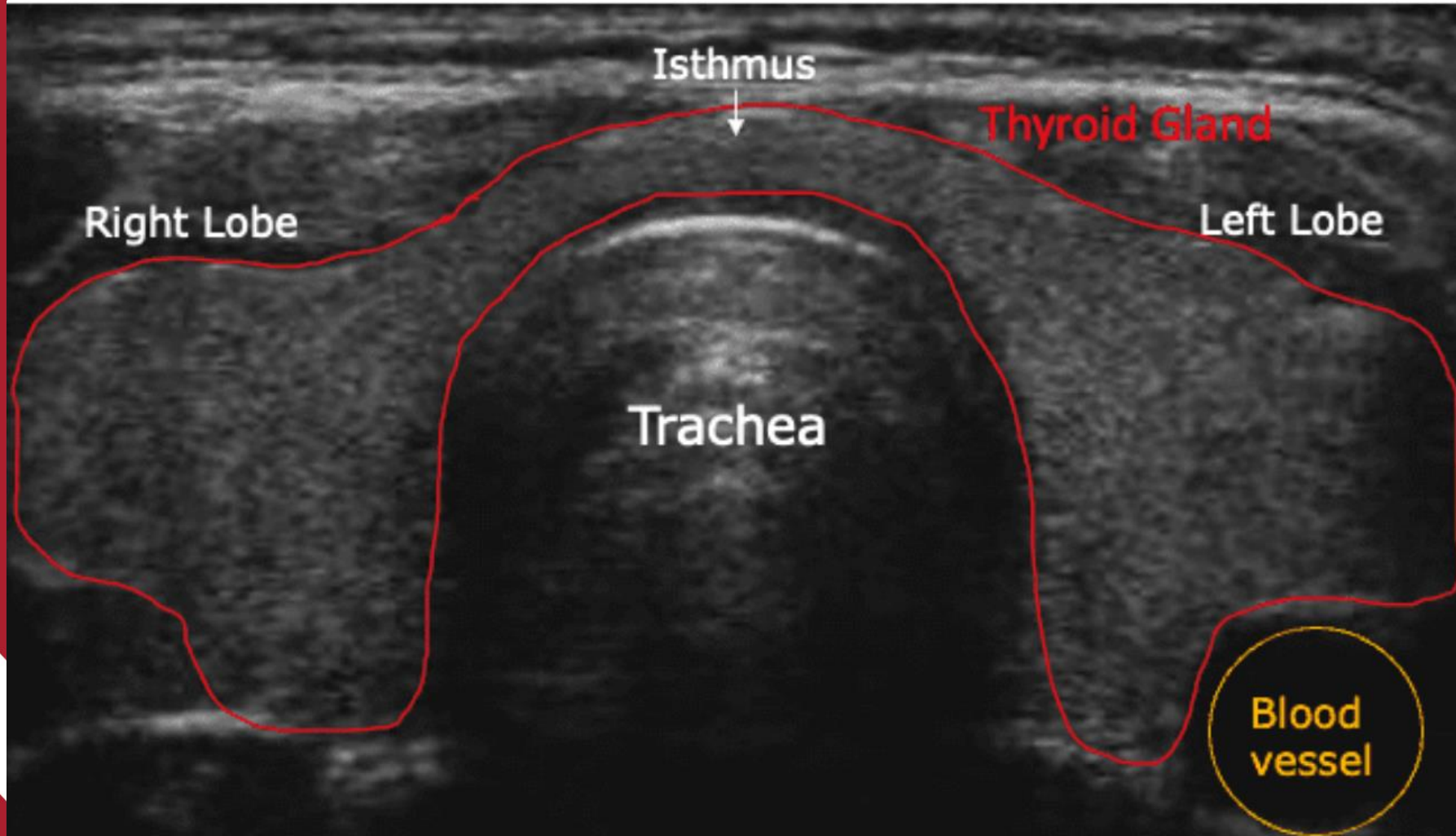
(can I get a picture of one of you with a Butterfly or other POCUS measuring someone's JVP for future slides?)

B Internal jugular vein

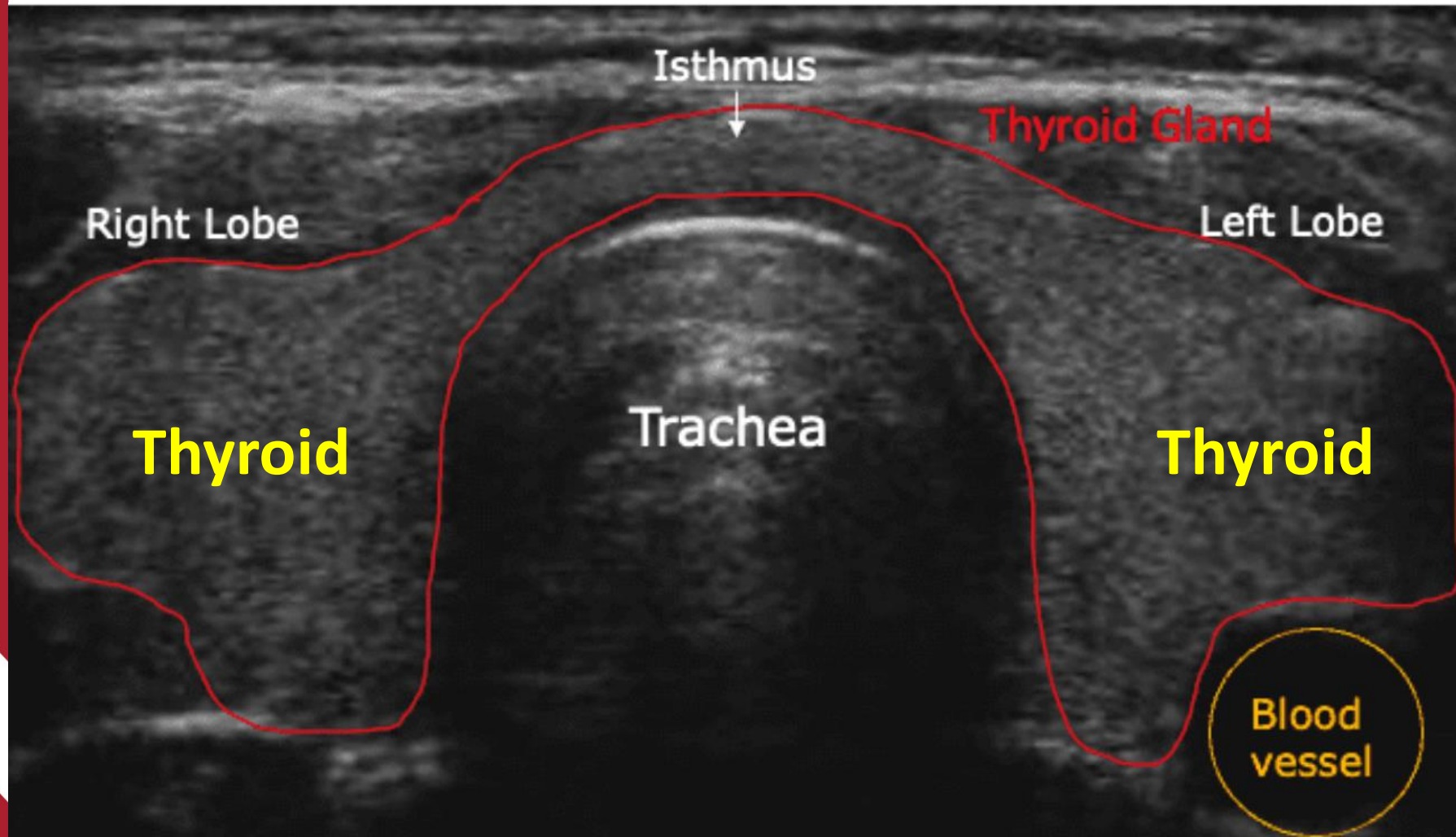


Start in the middle at the trachea

A-lines are seen in the trachea (air)

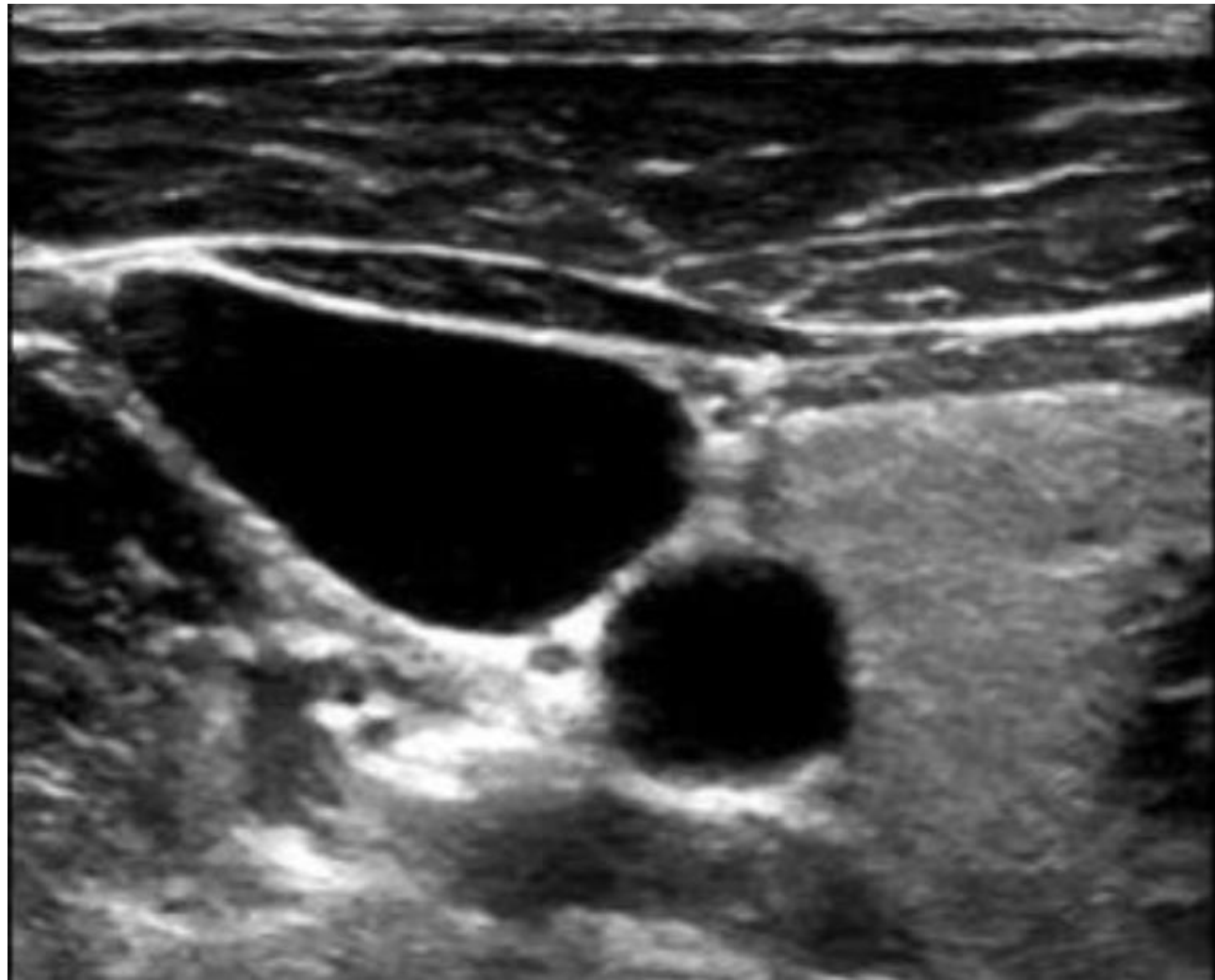


- # Thyroid is homogenous &
- adjacent to the thyroid is the
 - pulsatile internal carotid artery



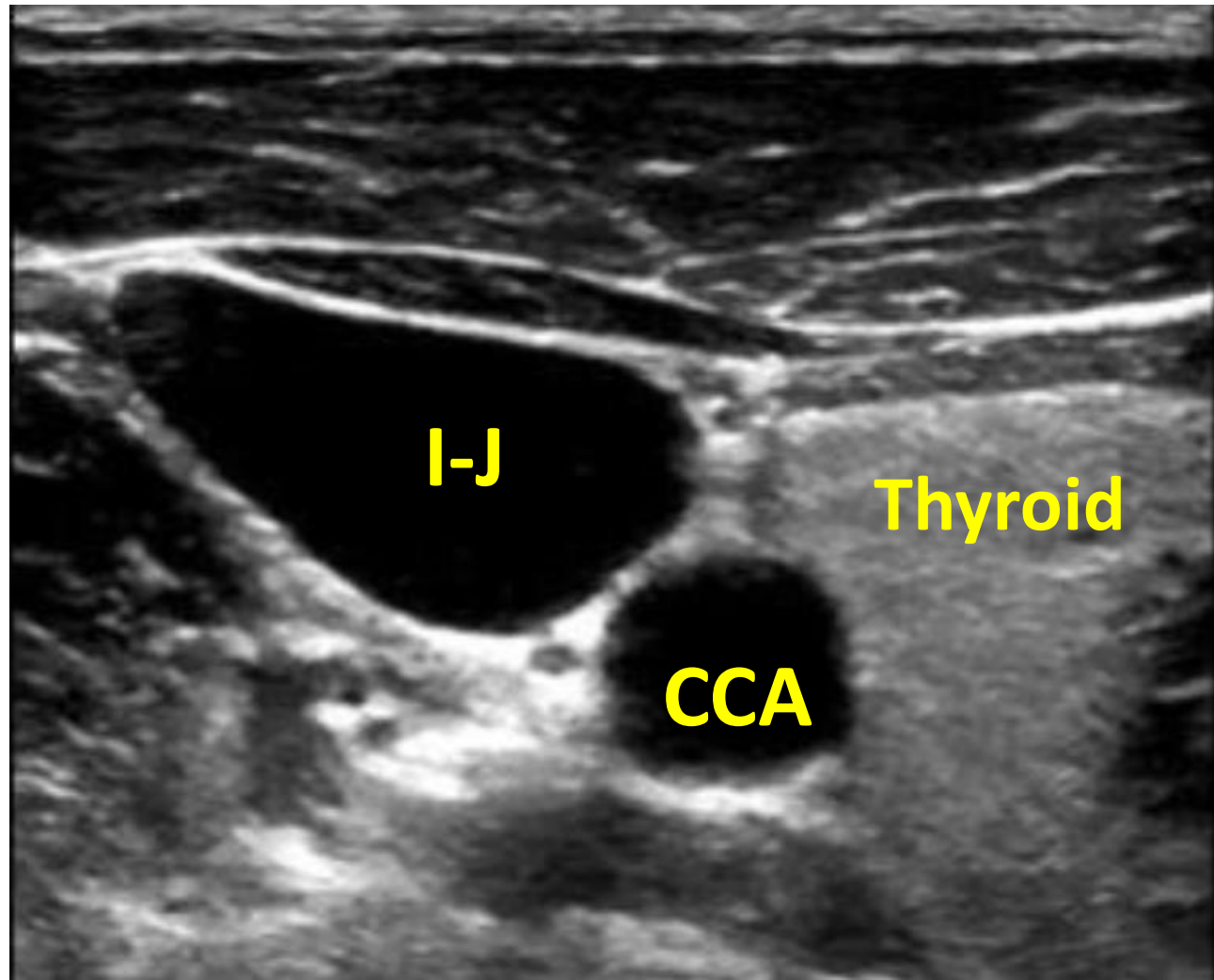
The internal jugular can be seen

- with a Valsalva or**
- blowing through pursed lips**



The internal jugular can be seen

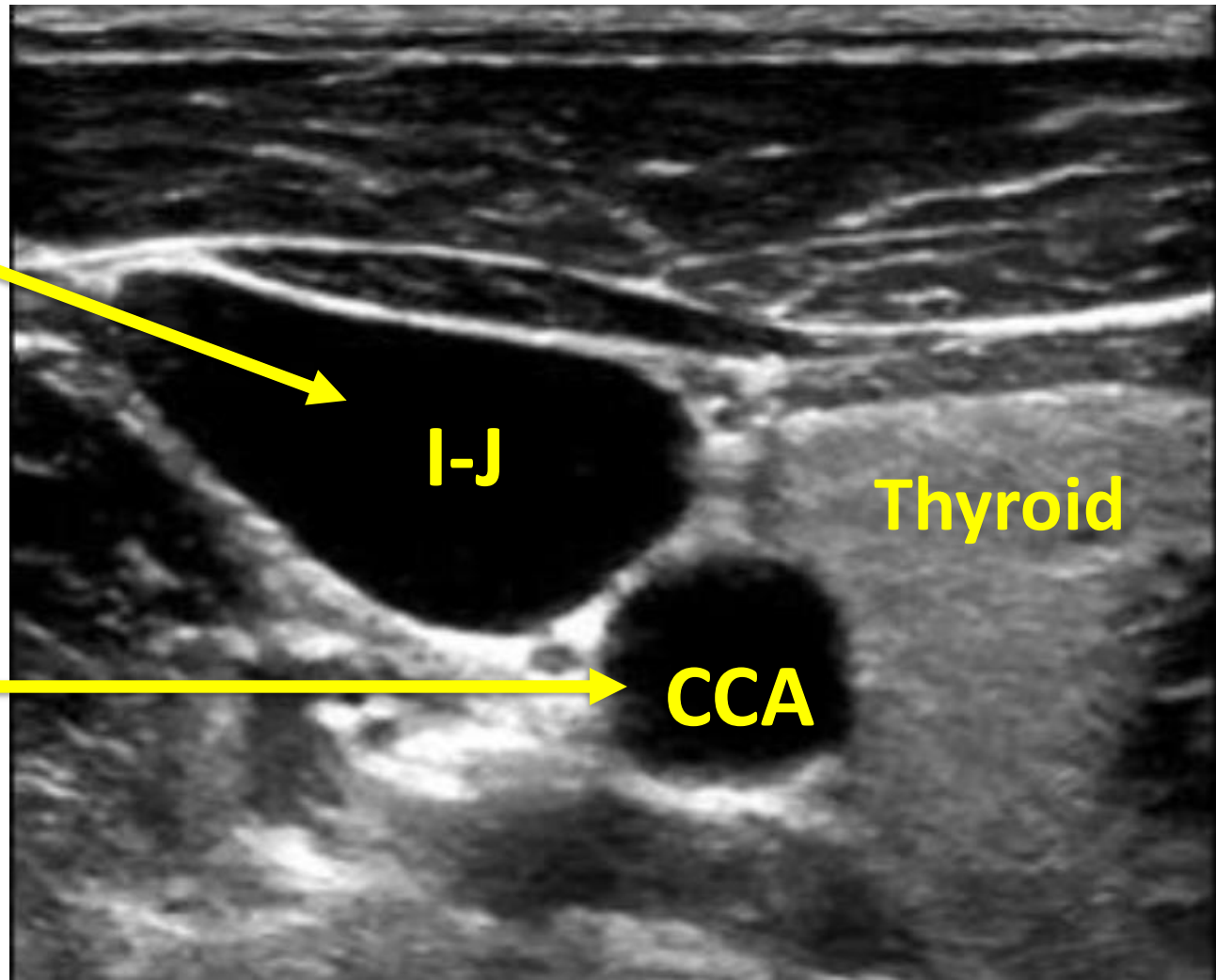
- with a Valsalva or**
- blowing through pursed lips**

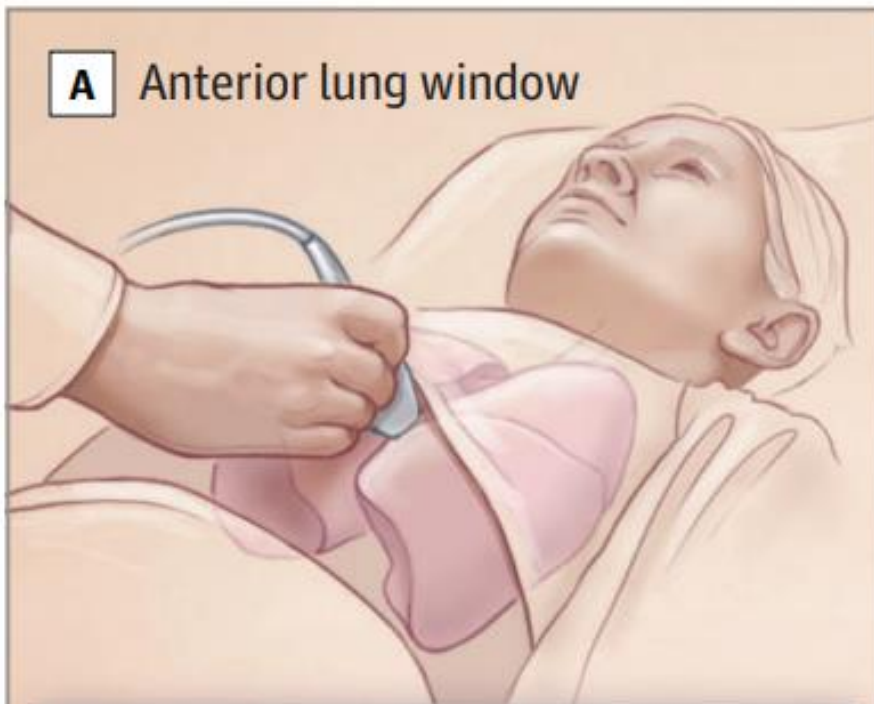


The internal jugular can be seen
- with a Valsalva or
- blowing through pursed lips

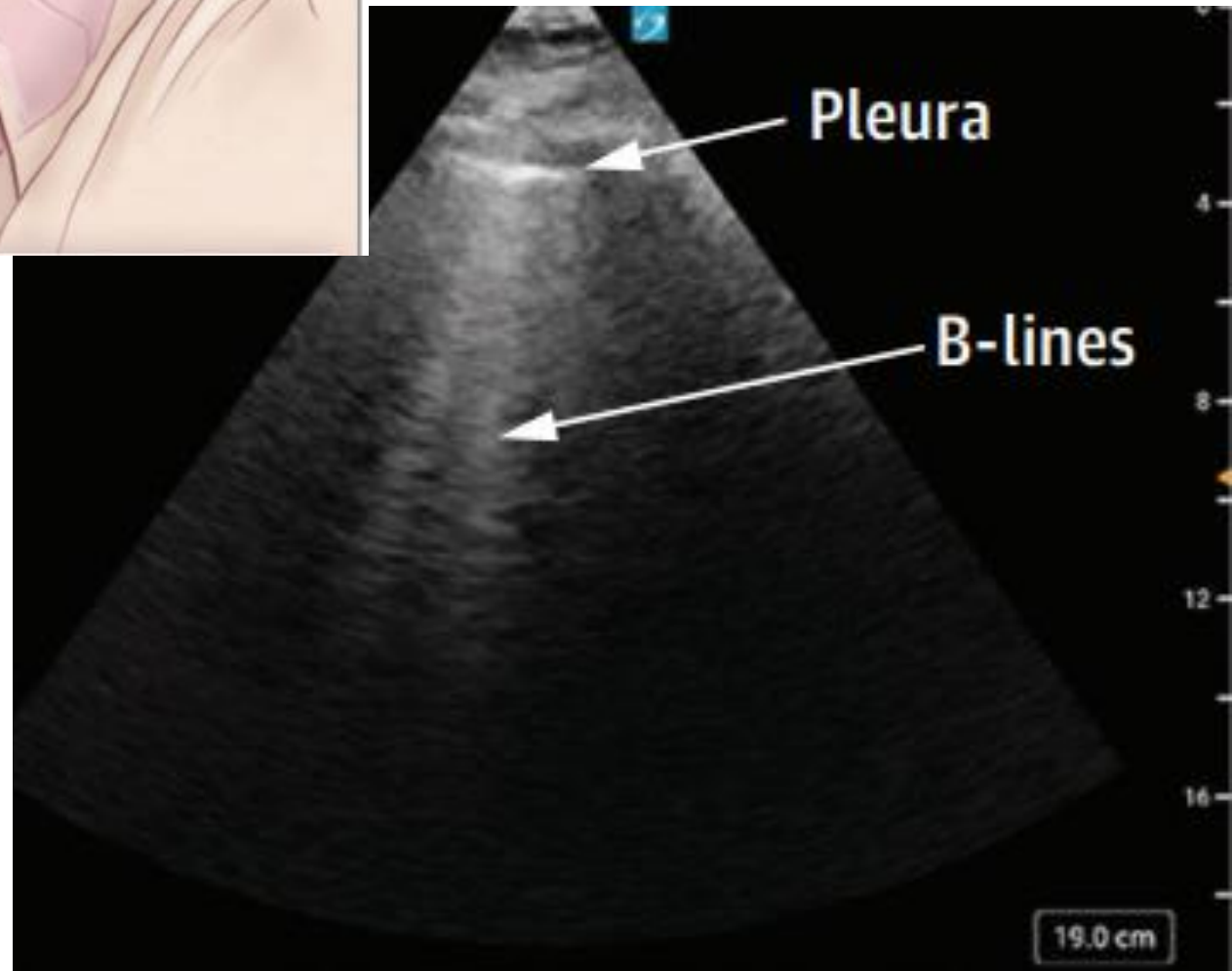
**Internal
Jugular**
(may be
flat at
first)

**Common
Carotid**
(pulsatile)





Scanning for “A” or “B” lines in the lungs



“A-Lines”
or “AIR”

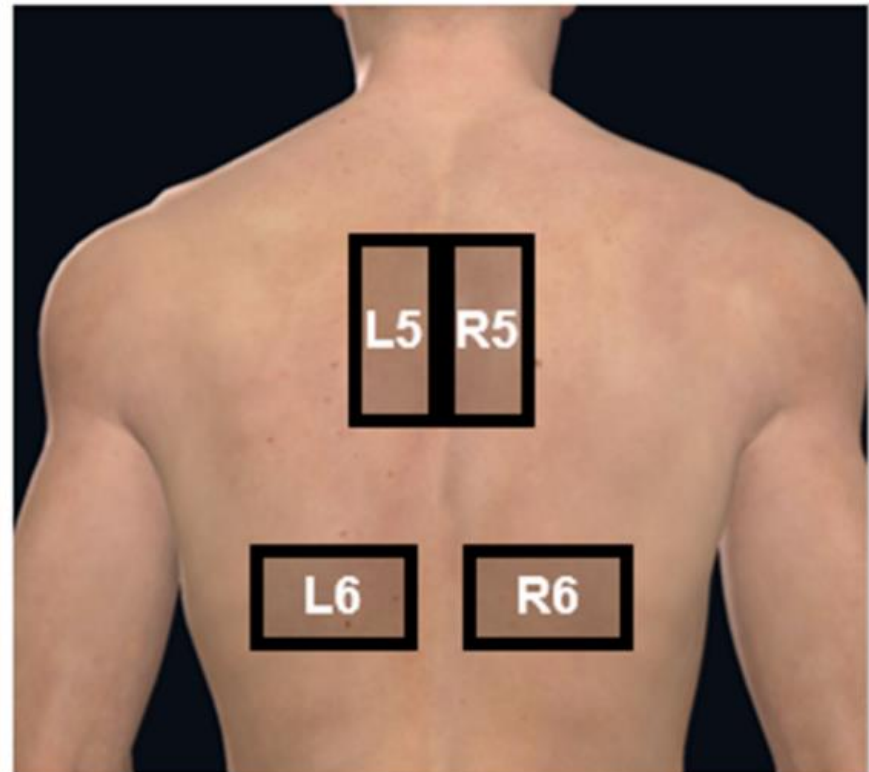
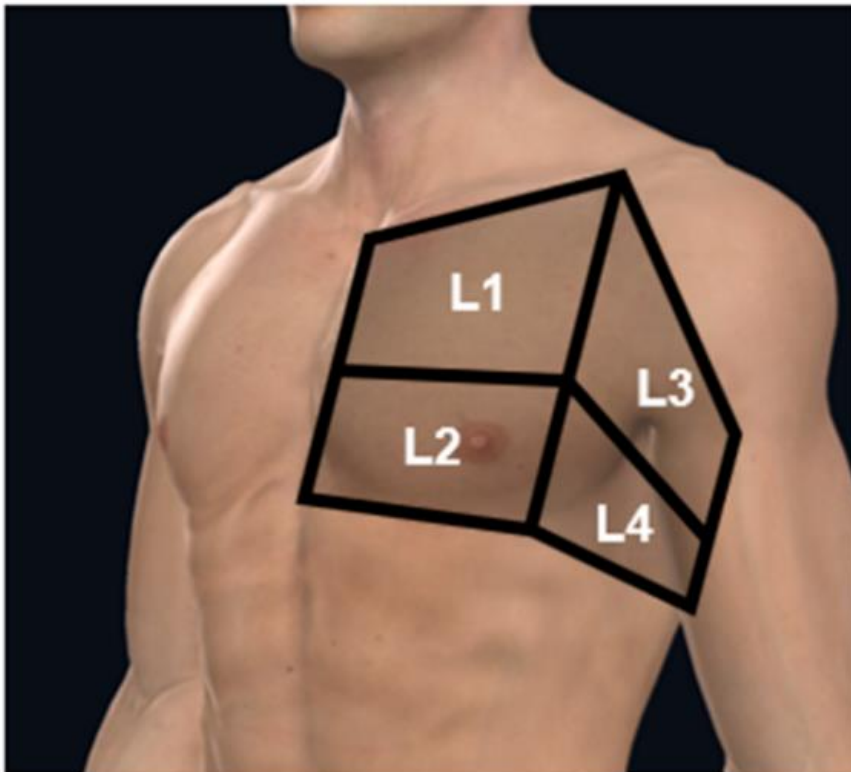
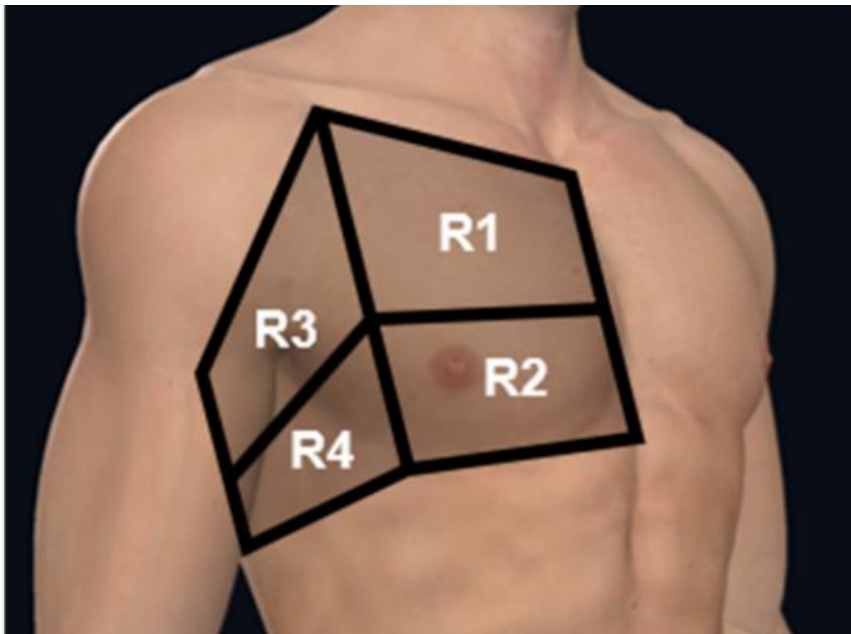
“B-Lines”
represent
alveolar
fluid

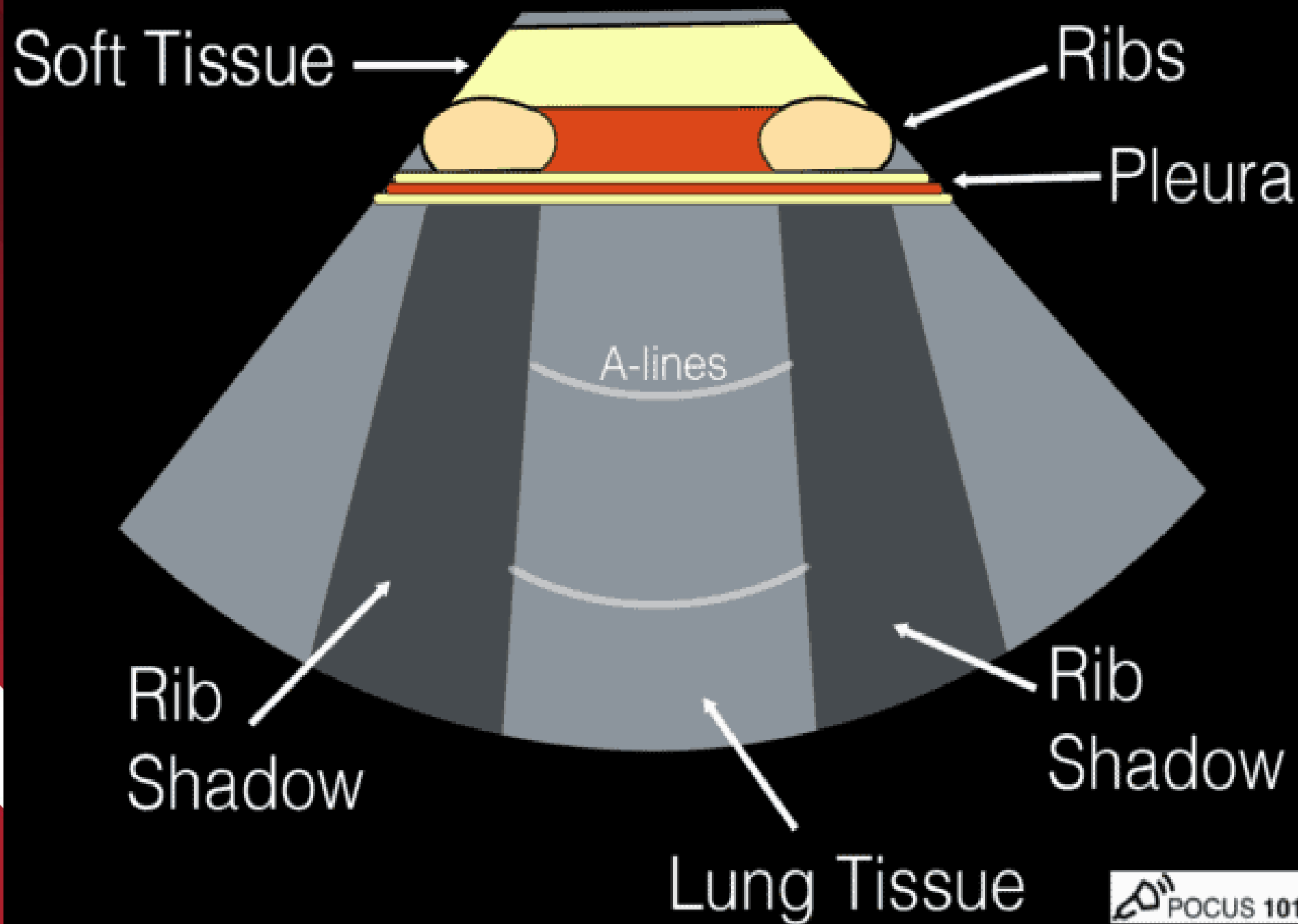
Zones for ultrasound

1-4 are often performed supine or up to 45°

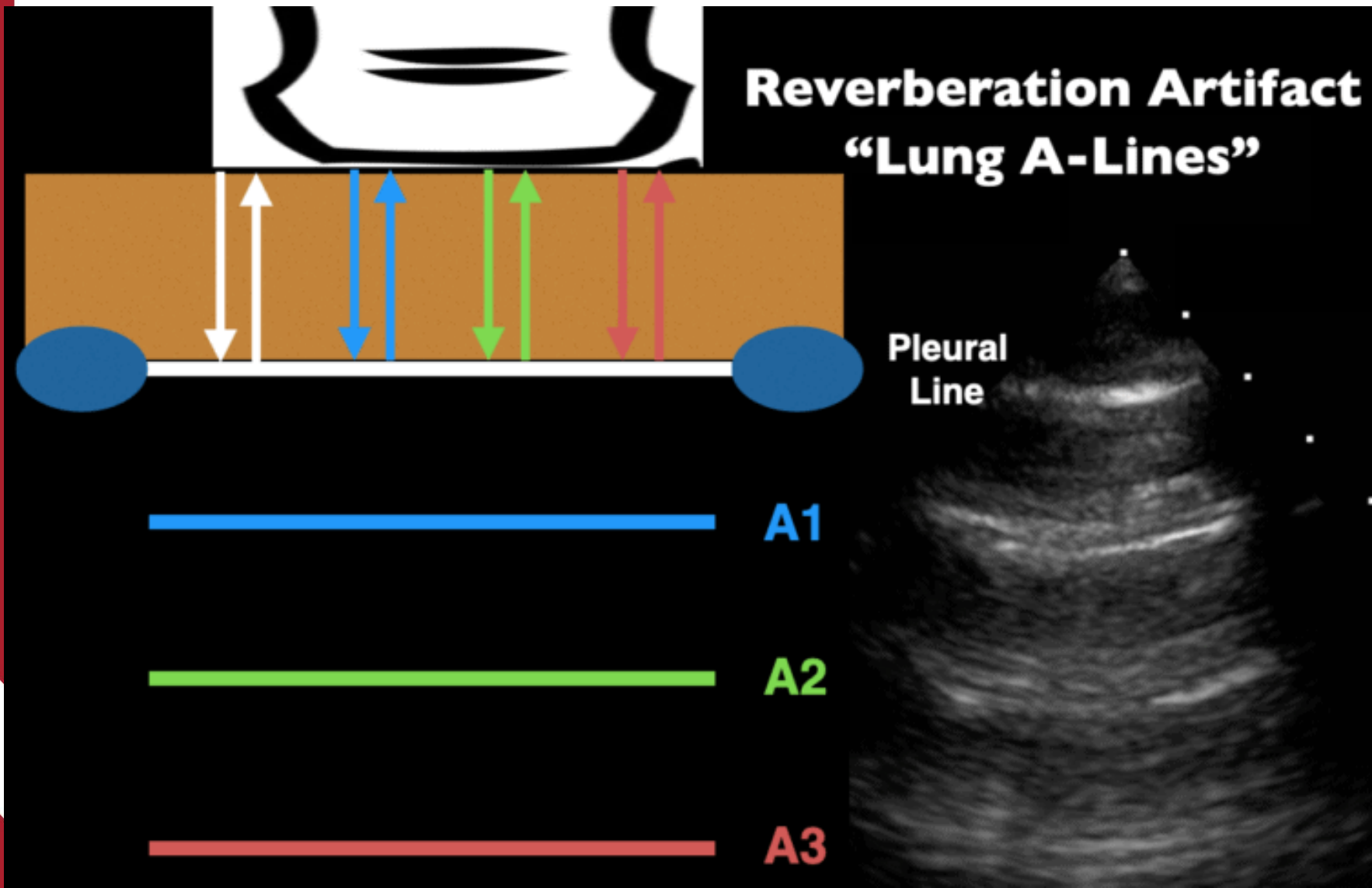
5-6 often omitted, but:

- performed sitting
- Helps ID effusions & pneumonias

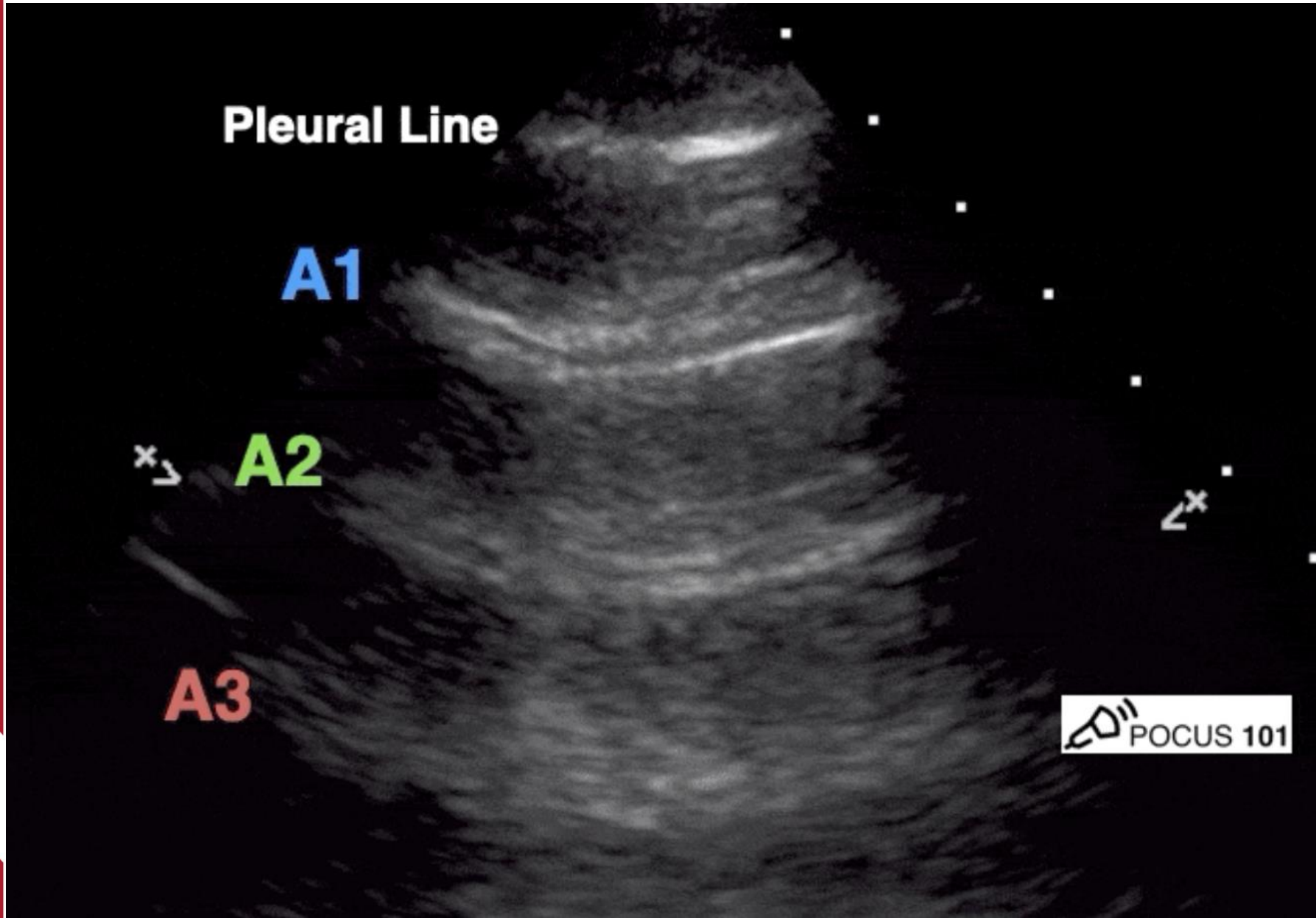




“A-Lines” are because of air in the lungs (normal)

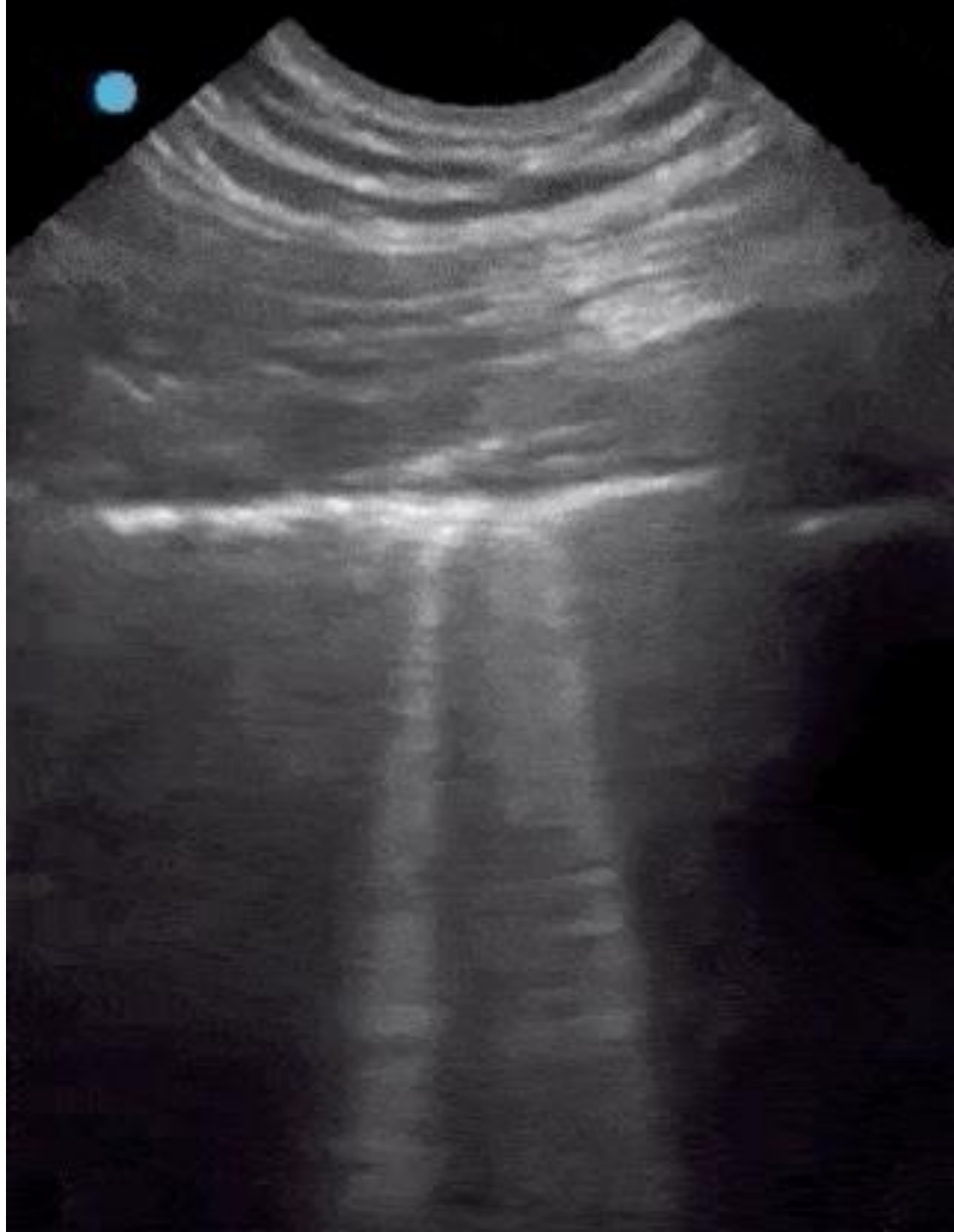

A-Lines (air, artifact, reverberations)



B-Lines: are like “beams through fluid”

- Usually “fluid” in the lungs
- Must extend the full length of screen
- $\geq 2-3$ per rib space
- B-Lines in one rib space is normal (often seen near diaphragm)
- Must be 2 or more rib spaces to be abnormal



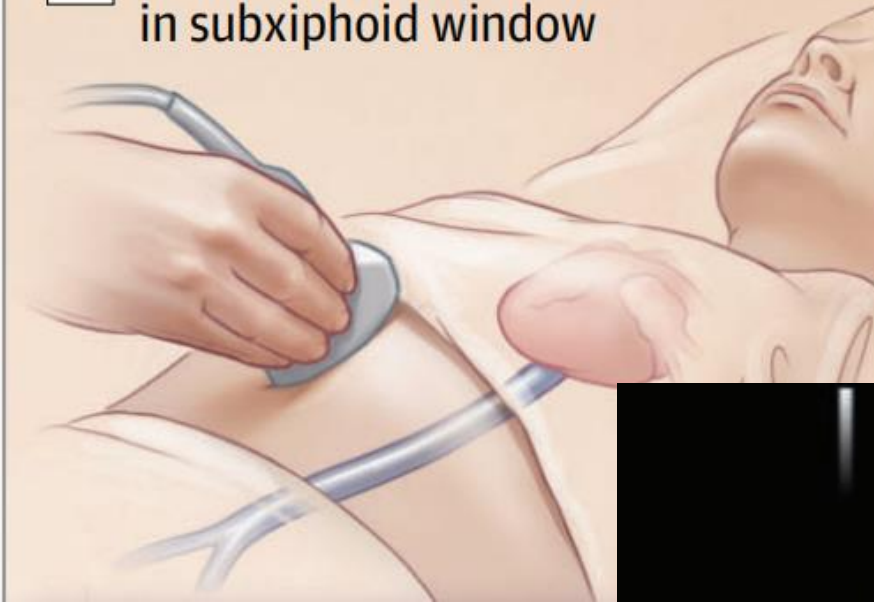Synthesizing the Hypoxic-POCUS Eval of the Jugular & Lungs

Jugular Venous Pressure (or HJR)	Pulmonary A-Lines “air-artifact”	Pulmonary B-Lines “beam-fluid”
Normal	Asthma COPD	ARDS Atypical viruses
Elevated	Pulmonary Embolism (↑ JVP only)	Heart Failure (JVP or +HJR)

Synthesizing the Hypoxic-POCUS Eval of the Jugular & Lungs

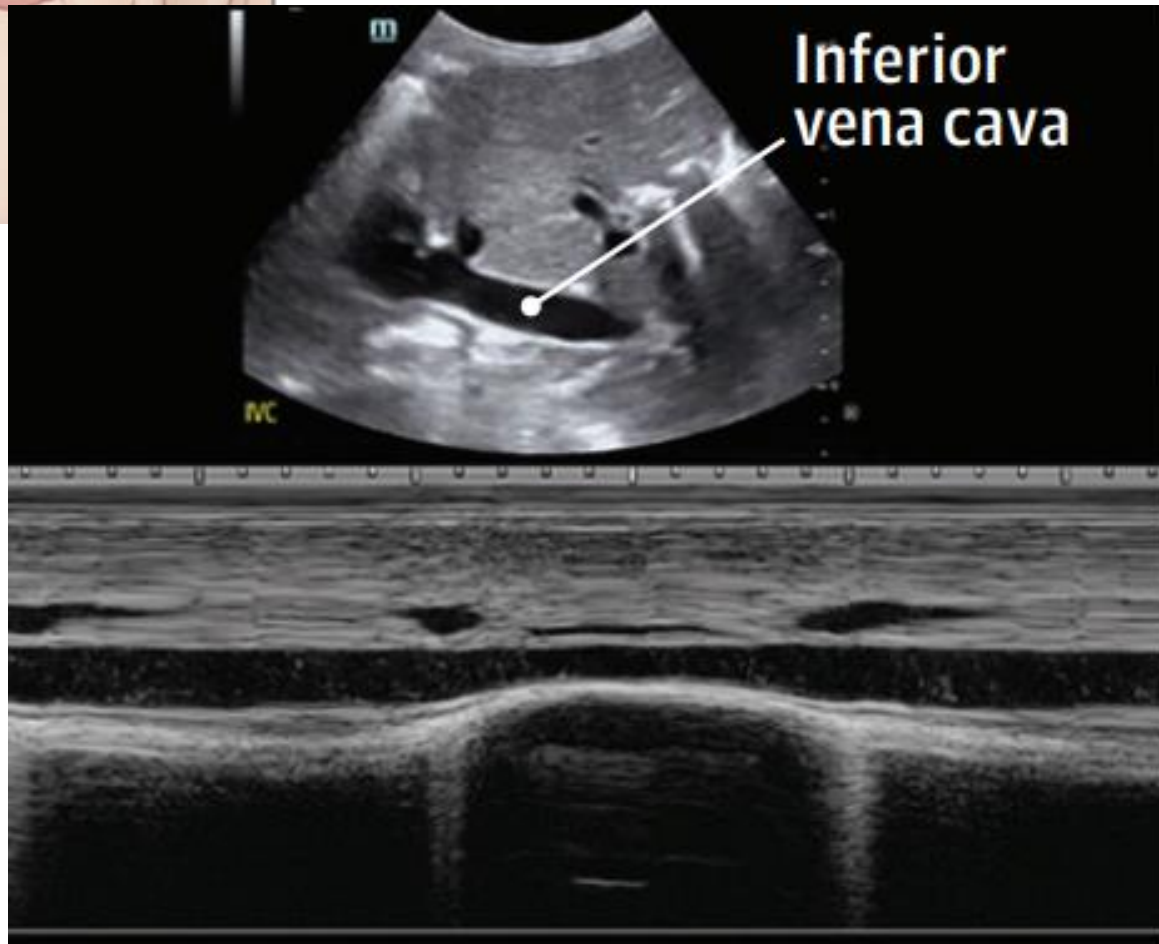
Jugular Venous Pressure (or HJR)	Pulmonary A-Lines “air-artifact”	Pulmonary B-Lines “beam-fluid”
Normal	Asthma COPD 15-30% wheezing absent in COPD	ARDS Atypical viruses
Elevated	Pulmonary Embolism (↑ JVP only) 5-15% can wheeze	Heart Failure (JVP or +HJR) 30% can wheeze

C Inferior vena cava
in subxiphoid window

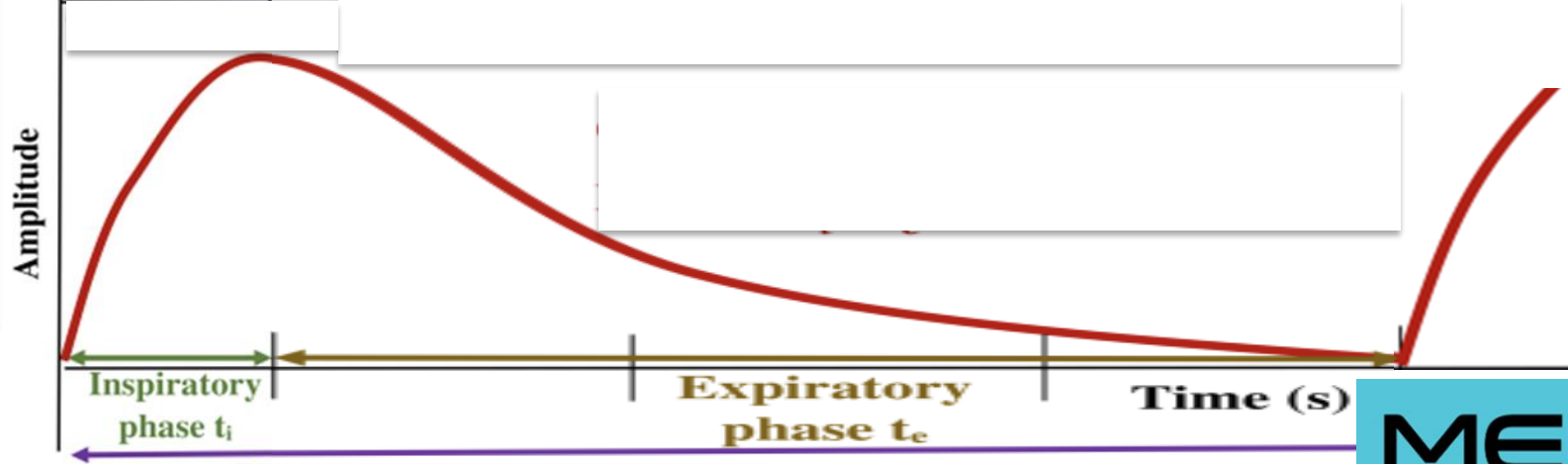
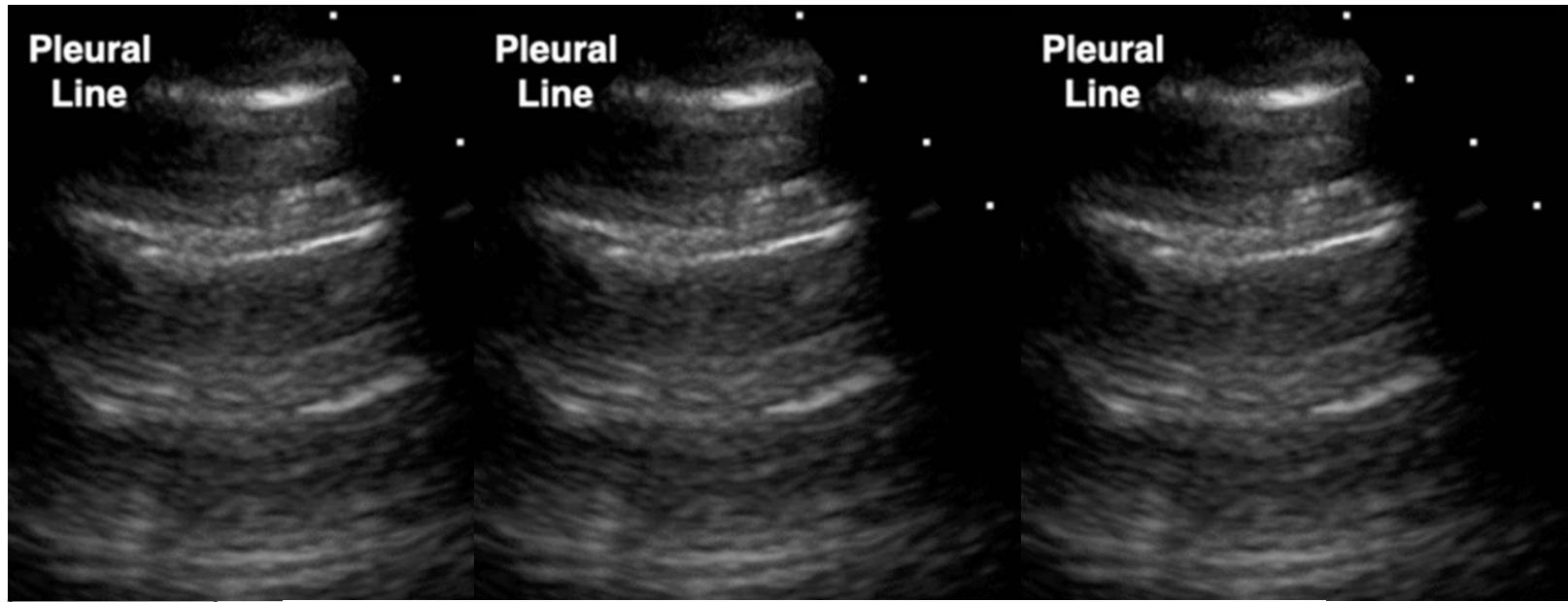


POCUS JVP is as accurate as the IVC measurement

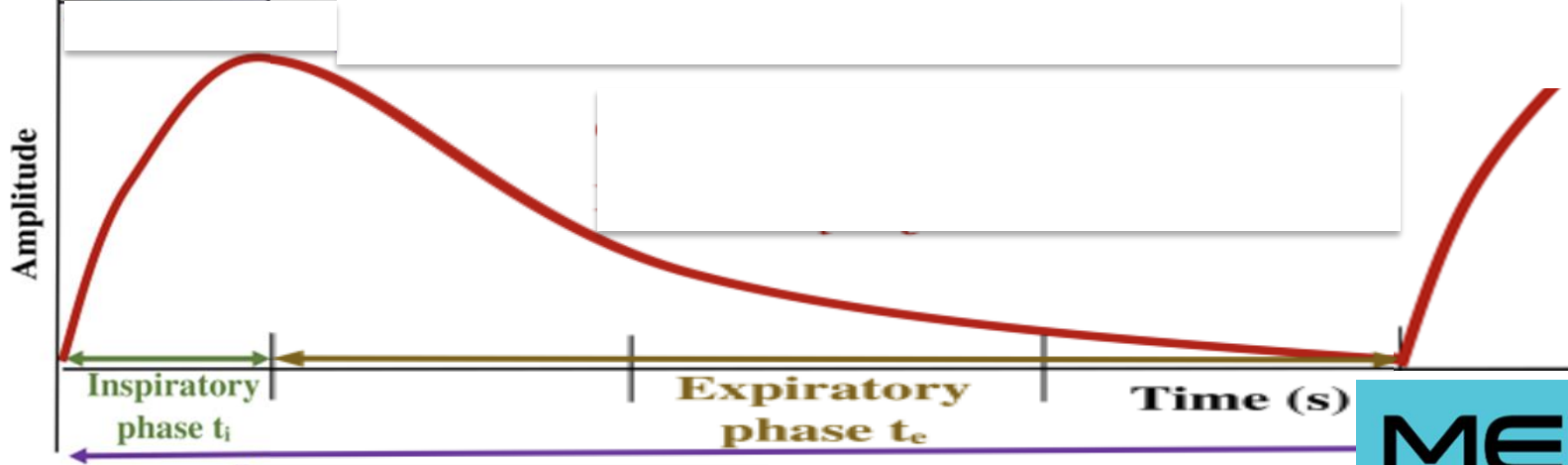
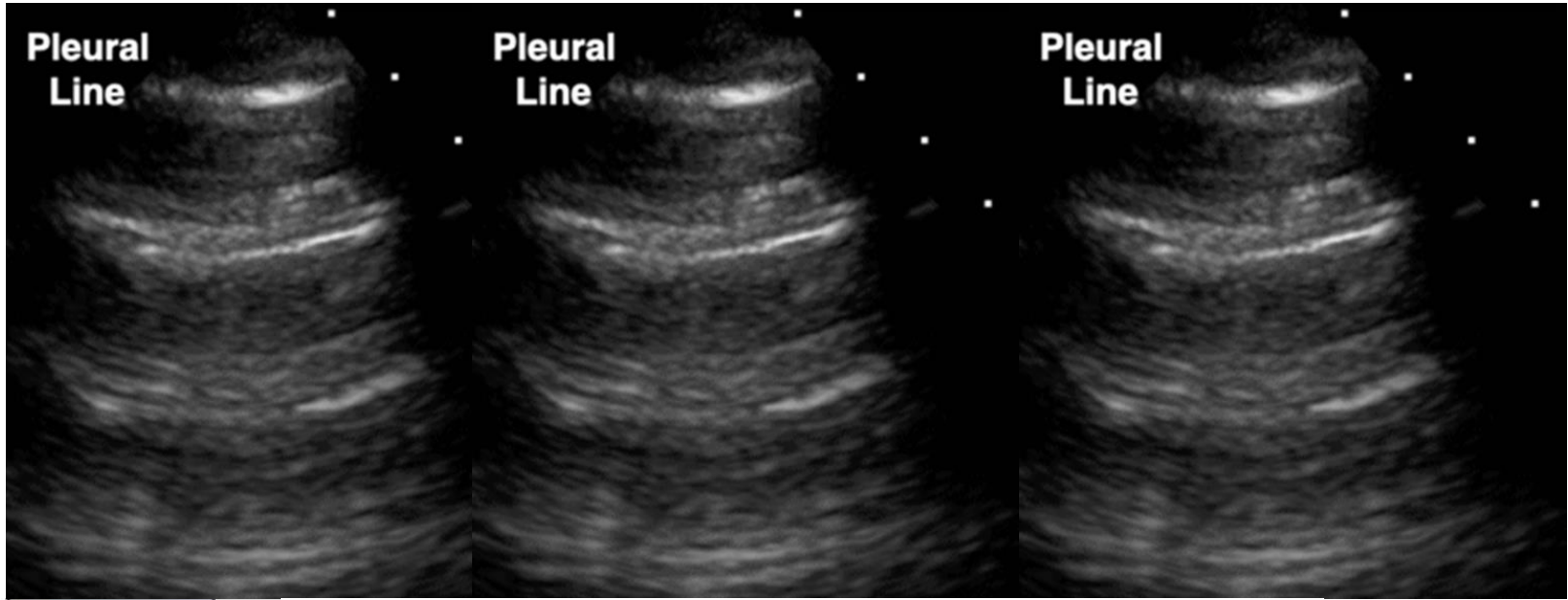
Cannot perform an AJR-HJR maneuver w/IVC view



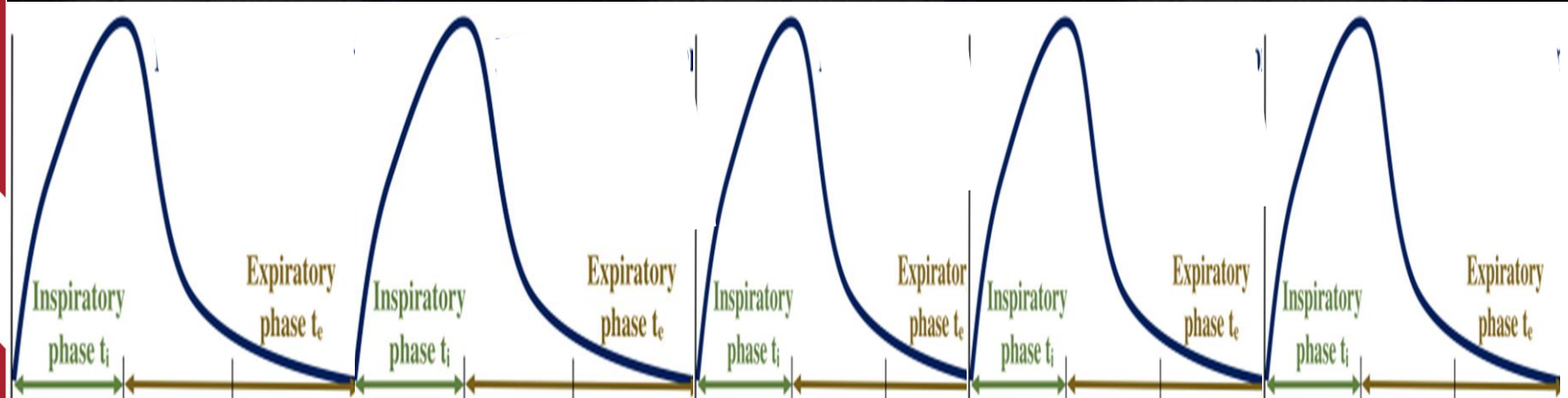
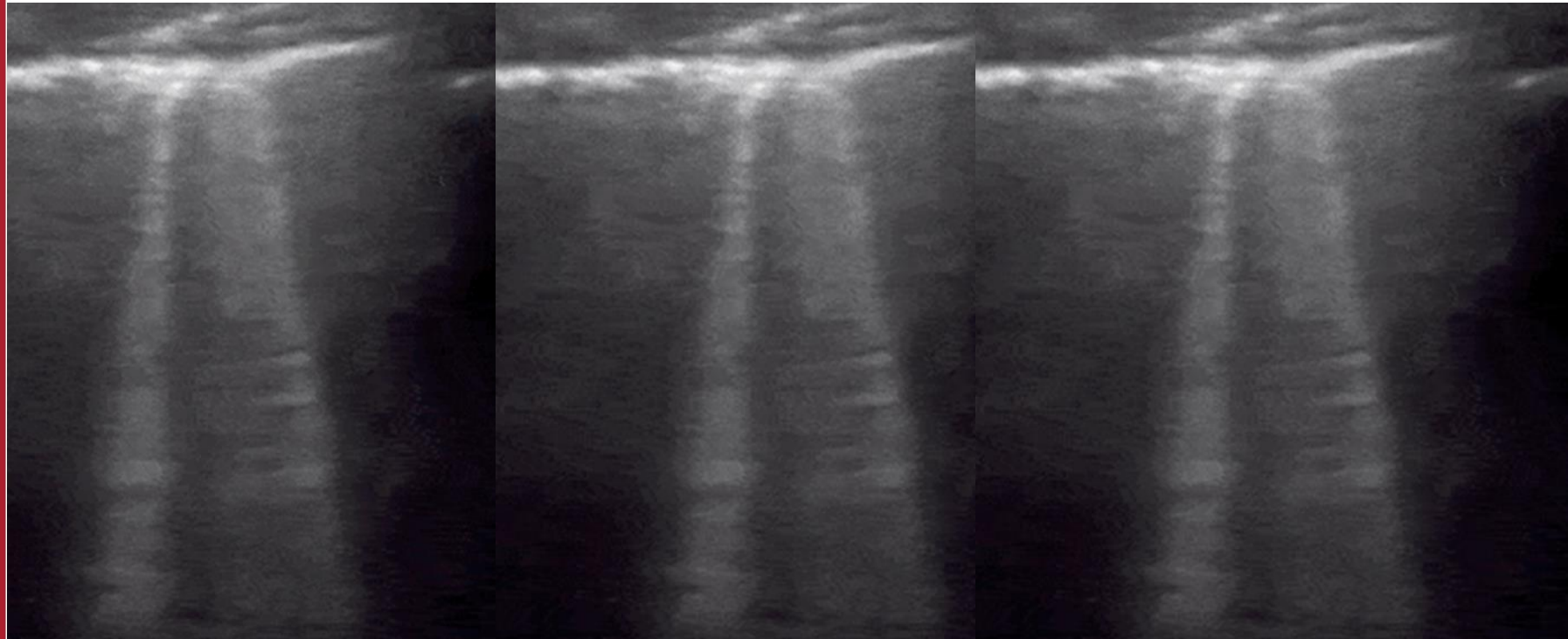
A-Lines with prolonged expiration (looking between many rib spaces)



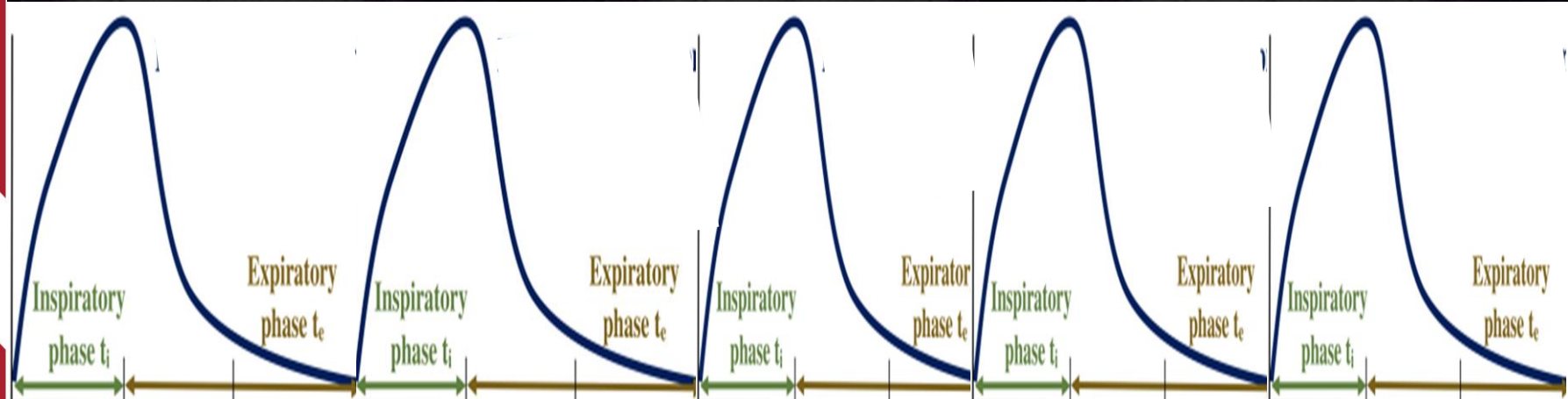
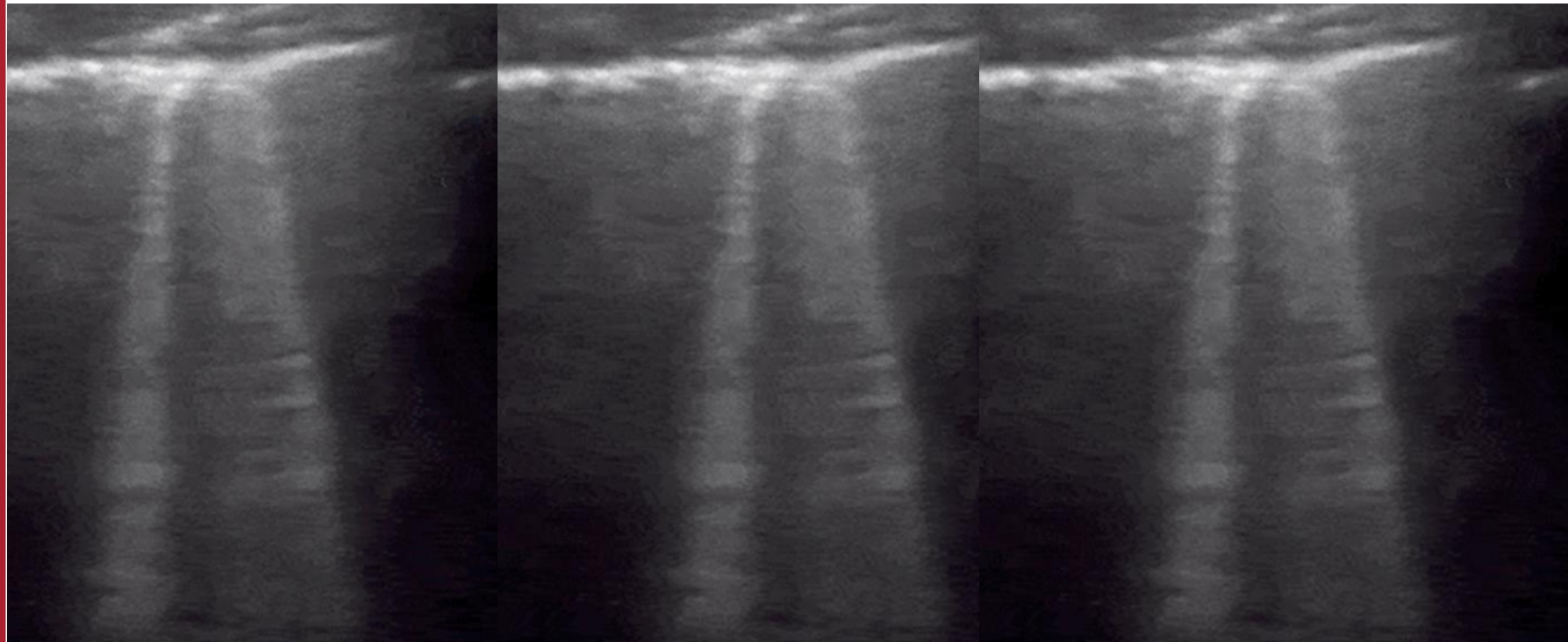
This is a COPD exacerbation; expiratory wheezing; +/- insp. wheeze



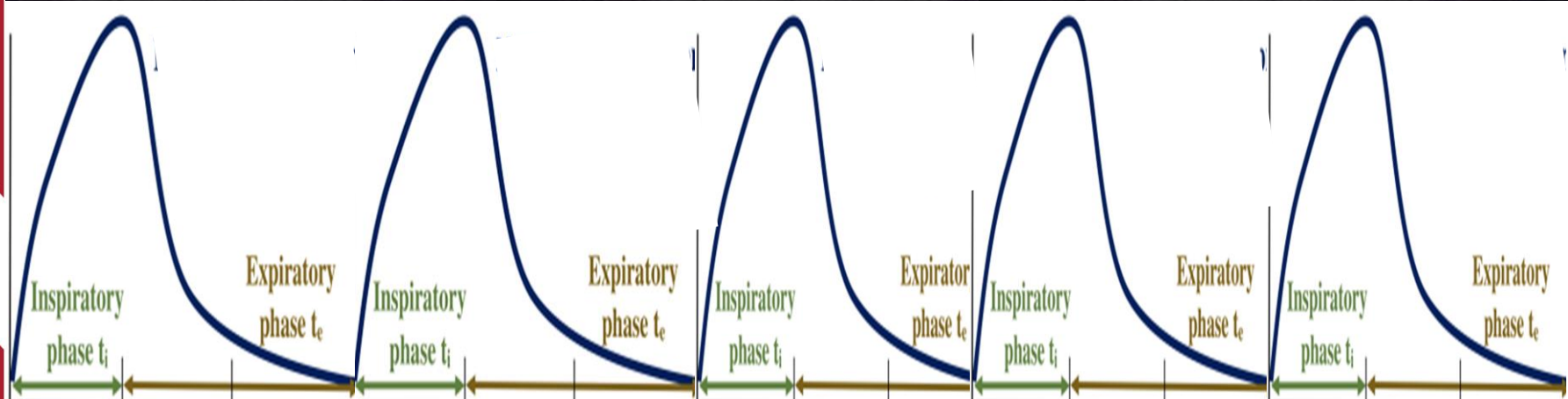
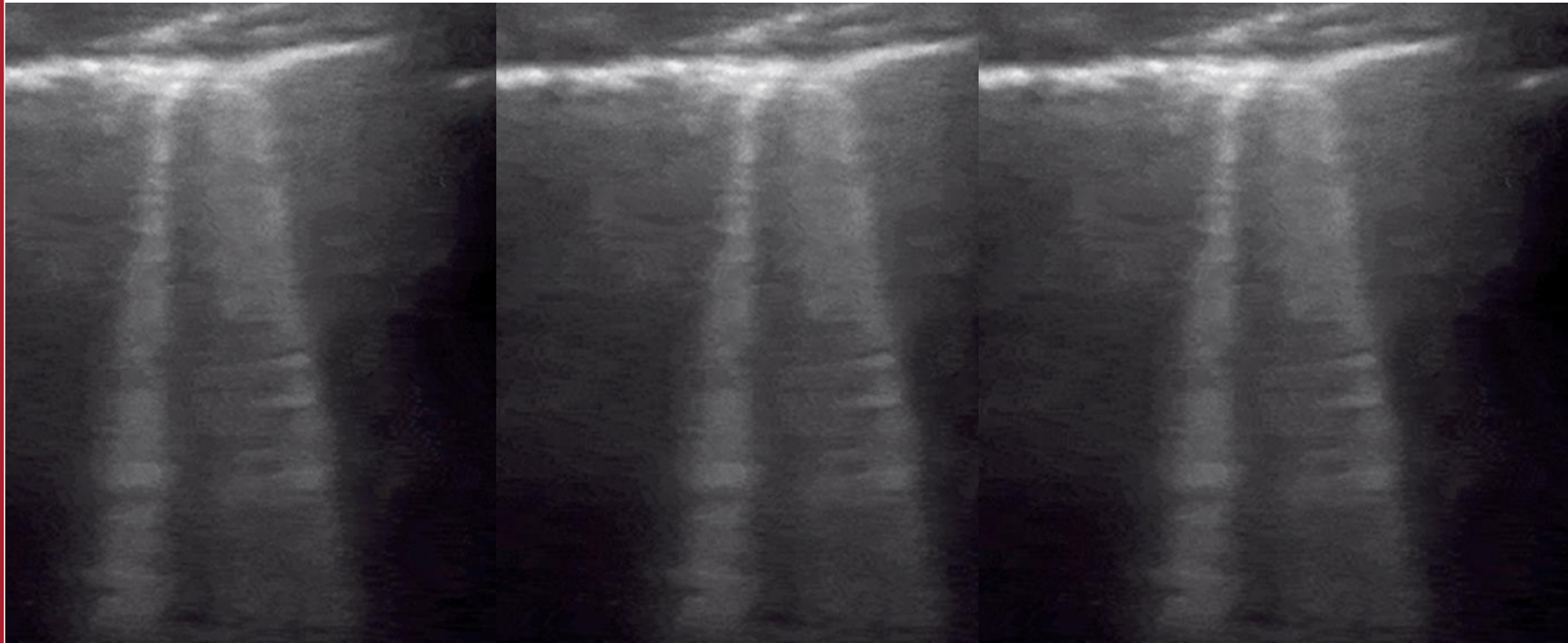
Hypoxic, History of “COPD” with prominent expiratory wheezing



Tachypnea & B-Lines; inspiratory to expiratory ratios about equal

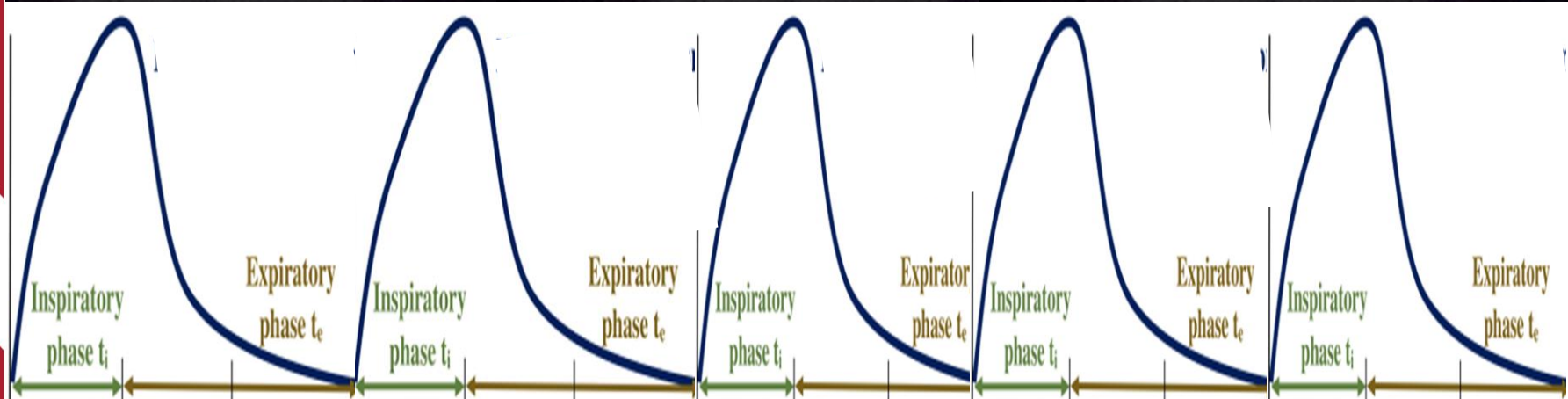
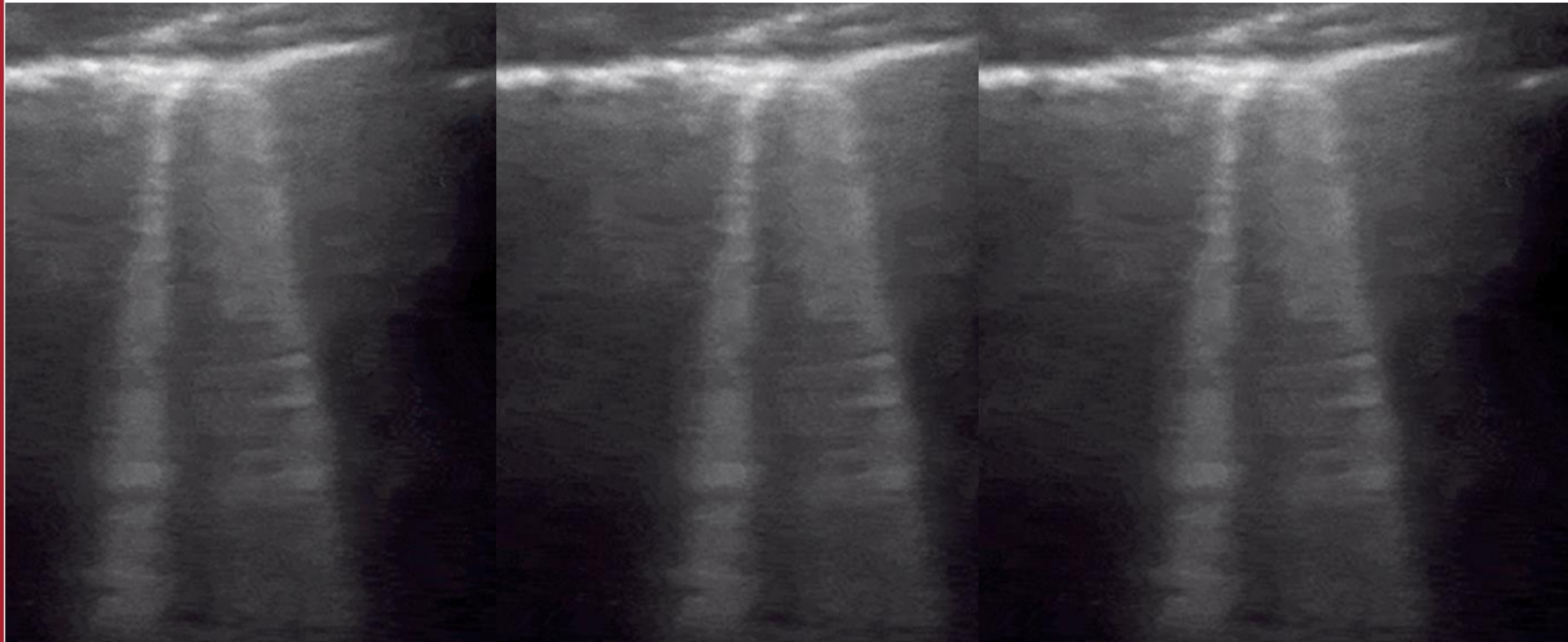


What is your diagnosis?

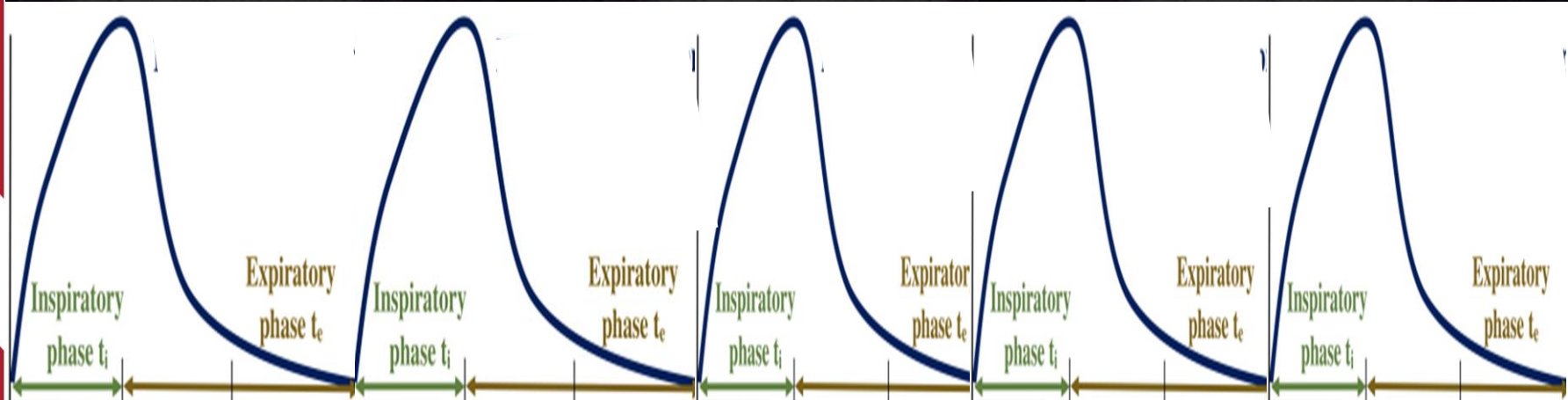
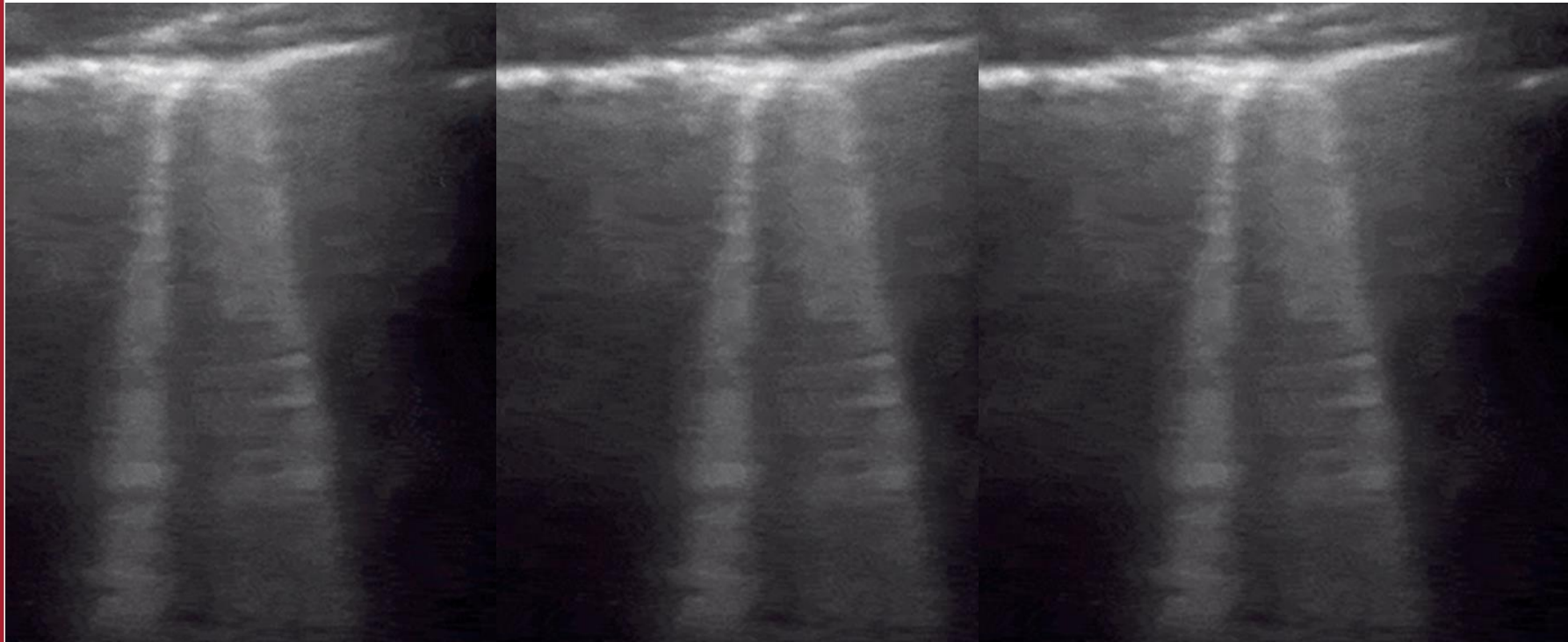


Heart Failure

This could wheeze, crackle/rales or be silent



Always correlate to clinical scenario, as sepsis & COVID could also look like this



The **KEY ISSUE** with JVP

- ❑ Must differentiate what is “back up” from the **LEFT SIDE** of the heart
- ❑ From that which is “back up” generated by the **RIGHT SIDE** of the heart
- ❑ **There will be JVP WITHOUT Failure in:**
 - ❑ **Pulmonary Hypertension, OSA w/TR-regurge**
 - ❑ **Cor Pulmonale with advanced COPD**
 - ❑ **Significant Pulmonary Embolism w/RV dysfx**
- ❑ **POCUS B-Lines** help differentiate
Left from Right sided dysfunction
- ❑ Sub-xyphoid or **parasternal short axis** views
can help suggest RV-dysfunction w/POCUS

J-LUX POCUS Protocol: For hypoxia & vascular volume

- ❑ **JVP/HJR:** Internal Jugular; clarity w/POCUS
- ❑ **L Lungs:** POCUS Findings in the Lungs:
 - ❑ A – Lines; Artifact from Air in lungs (normal)
 - ❑ B – Lines; like “Beams of light” thru clouds
 - ❑ C – Consolidation-hepatization (pneumonia)
 - ❑ D – Diaphragm &/or Dark Fluid (eg effusion)
 - ❑ E – Expiration (Insp:Exp ratio w/wheezing)
- ❑ **U Upper Abdomen, sub-Xiphoid view**
 - ❑ Ejection Fraction (good or bad EF?)
 - ❑ Inferior Vena Cava for Right Atrial pressure
- ❑ **EXacerbation Eval:** synthesize history, exam, labs & imaging for the root cause

Conclusion

- Measure the JVP-AJR/HJR
 - POCUS can assist
 - Much easier than measuring the IVC
- Lungs; beyond sounds
 - Observe the Inspiration:Expiration ratio
 - POCUS for A-Line or B- Lines
- Suggested starting point to learn POCUS
- How easy/difficult will this be to start incorporating this type of POCUS into all of our admissions with hypoxia?

QUESTIONS

???



BACK-UP SLIDES

How to determine if there is LV failure ON TOP of Pulmonary HTN

- ❑ **≥ 4 cm of HJR on top of JVP \Rightarrow LV failure**
 - ❑ Can confirm with POCUS B-Lines
- ❑ **There will be a need for a “baseline elevation in JVP” for needed Pre-Load, e.g.**
 - ❑ Pulmonary Hypertension, TR-regurge
 - ❑ Failure from an acute Inferior MI w/RV dysfx
- ❑ In practice, I permissively allow $\sim 12-15$ cm JVP, depending on the degree of Pulm HTN
- ❑ **Then DIURESE the HJR to the JVP**
(essentially diurese until the HJR disappears)
- ❑ **And B-Lines should also disappear**

Diuresing acute HFrEF by HJR with Pulmonary HTN-TR (pre-existing ↑ JVP)

- Diuresing acute HFrEF with pulmonary HTN or core pulmonale can be difficult
- Pre-existing elevated JVP with RV dysfunction
- Confirm (+) HJR of ≥ 3 cm (or JVP to the jaw)
- Diuresis until the HJR $\leq 1-2$ cm
- There needs to remain a good PreLoad with significant RV dysfunction, hence JVP of ~ 12 cm may need to remain
- See next slides about POCUS so as to assist in the diagnosis and diuretic management